Kantonsspital Baselland

DIAGNOSTIK SCHMERZHAFTER PROTHESEN DER DISTALEN EXTREMITÄT

SPECT-CT - Benefit oder „Nice“ to have

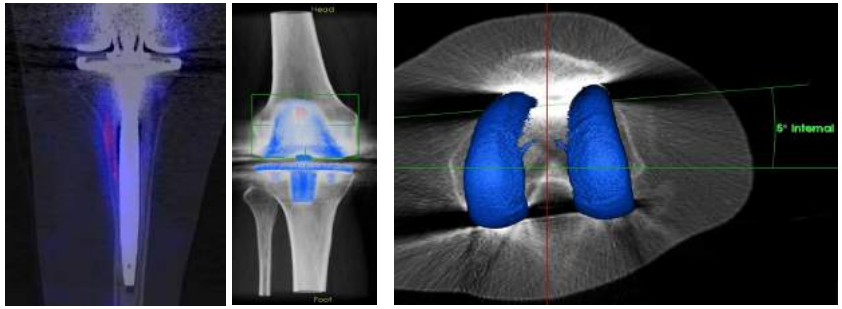

H. Rasch

Institut Radiologie u. Nuklearmedizin/ Bruderholz

BDN Tagung 9/2023

AGENDA

SPECT CT

- Was ist das?
- Untersuchungsablauf
- Technische Hinweise
- Was sehen wir? Biologie! Biomechankik!

Cases

- Hüftprothetik
- Knieprothesen – Total /Schlitten
- OSG Prothesen
- Infektionen
- Weichteile

Zusammenfassung / TAKE HOME MESSAGES

SPECT-CT

Untersuchungsablauf

0 // 2-3 *h*

früh15min

- „Perfusion Phase“
- „Bloodpool –Phase“ SPECT

spät~40min

- GK ap / pa
- SPECT
- und low dose CT

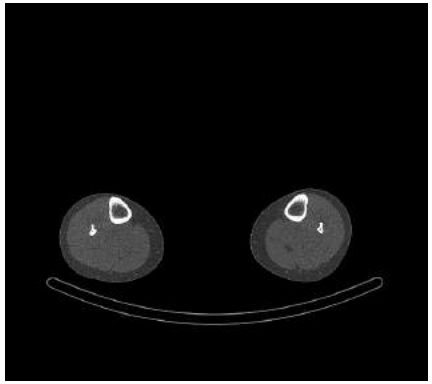

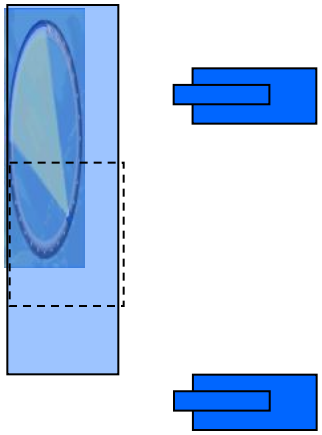

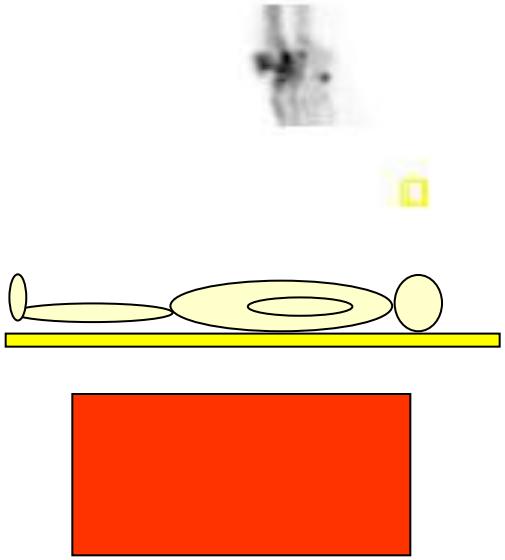

SPECT-CT

Bloodpool SPECT

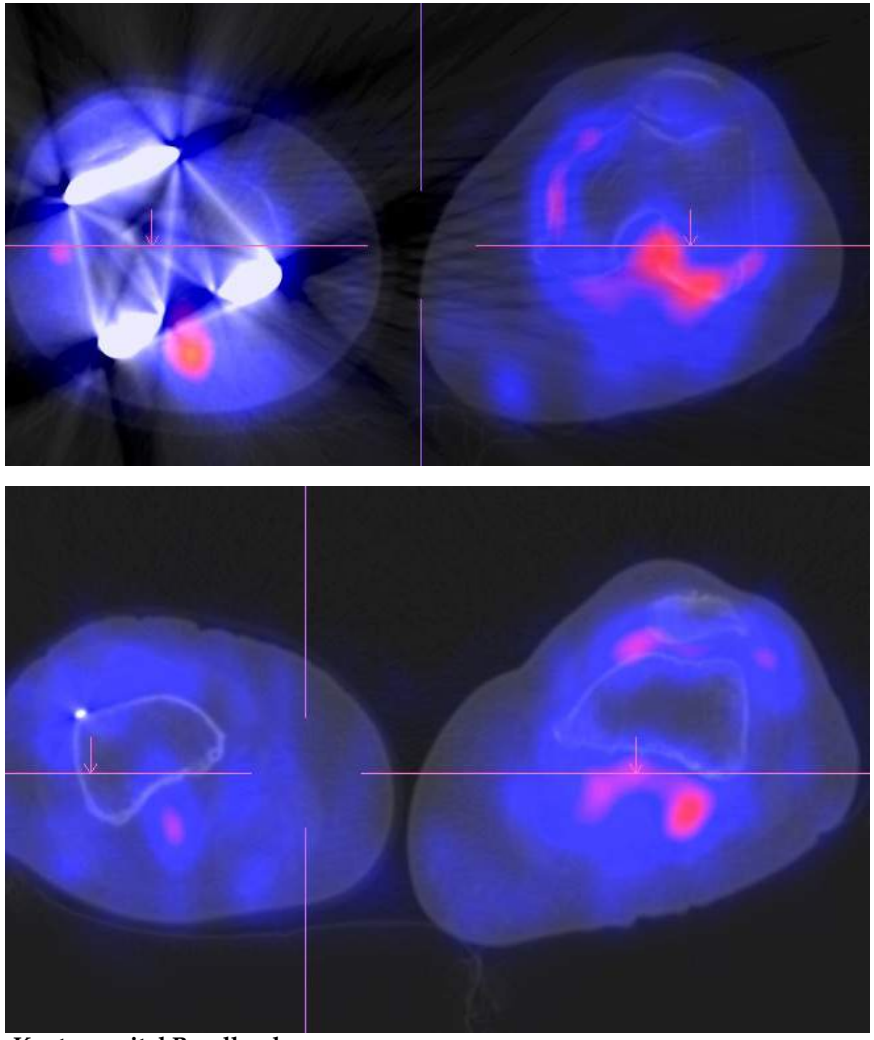

Optimaler Vergleich zu Late SPECT

Technische Hinweise

Extended Scale CT Rekonstruktion



Technische Hinweise

Extended Scale CT Rekonstruktion





iMAR

Dual Energy

Monochromatisch

SPECT-CT

Was führt zu Uptake?
Biologie = Biomechanik!

- Tracer: 99m-Tc markiertes Biphosphonat
  - Chemabsorption – Bindung an Hydroxyapatit
  - regionale Perfusion
  - Osteoid

- Osteoblastische Aktivität
  - Mechanorezeptoren
  - Reaktion auf Biomechanik

- SPECT = „3D - Bild der Osteoblastenaktivität“

- Problem Osteolysen / Granulome!
  - – diagnostische CT Bildgebung essentiell

MRI KANN DAS AUCH - WIRKLICH?

Bone bruise = Uptake?

Szintigraphie

- Bessere Korrelation mit Schmerz
- Besssere Predictor für Schmerz

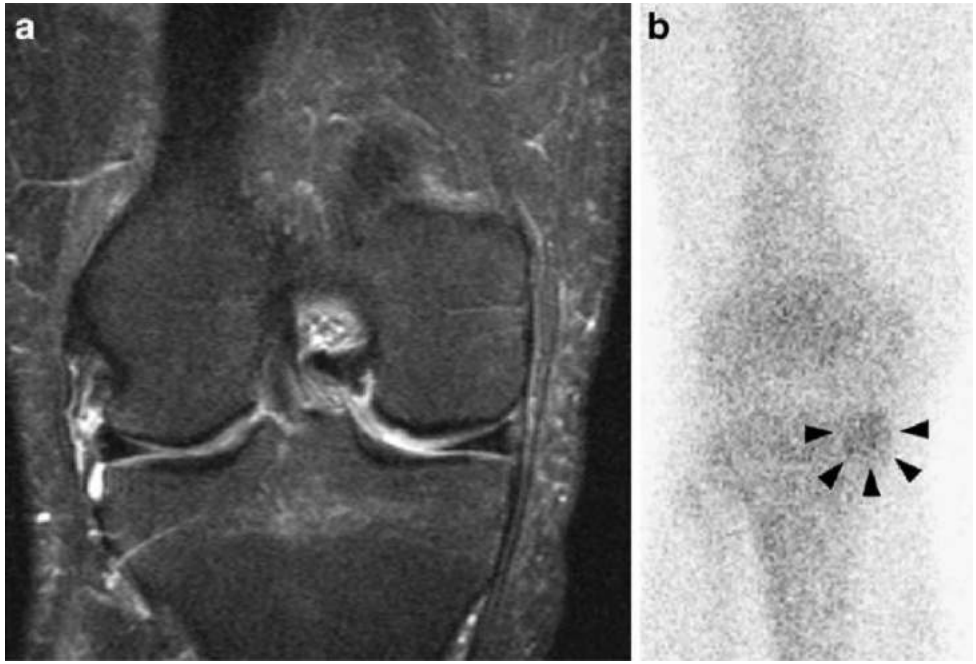

✸ *Buck FM, Hoffmann A, Hofer B, Pfirrmann CW, Allgayer B.*
Chronic medial knee pain without history of prior trauma: correlation of pain at rest and during exercise using bone scintigraphy and MR imaging.
Skeletal radiology. 2009 Apr;38(4):339-47

Kantonsspital Baselland

HÜFTPROTHETIK

Hüftprothesen - Probleme

Orthopäde will ALLES! Wissen – **SPECT gibt Antworten**

- Aseptische Lockerung – Partikel Abrieb – PE WEAR
- Infekt
- Positionierungsfehler / Komponentenlage
- Weichteilprobleme
- Iliopsoassehne
- Pseudotumoren

Hüftprothetik – Case 1

- F, 72 Jahre
- THR rechts 1998
- THR links1990
- Revision links 2008
- 10/2012 Kontrolle:
- Trauma vor 3 Wochen
- Kein Ruheschmerz, Schmerzen beim Laufen

- Klinisch: V.a. Lockerung

Hüftprothetik – Case 1

Hüftprothetik Case 1

Nur Lockerung?

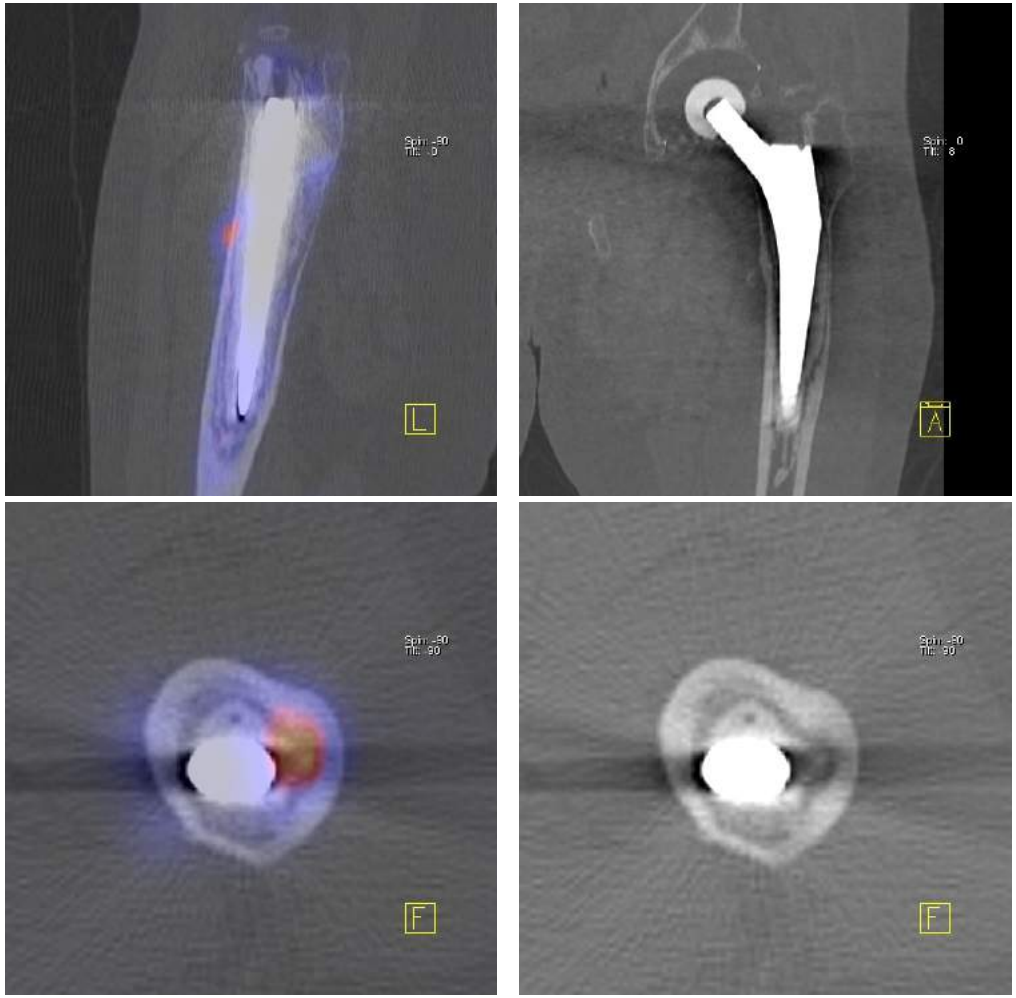

Hüftprothetik – Case 1

Lockerung **und** Fraktur - OP Plannung entscheidend!

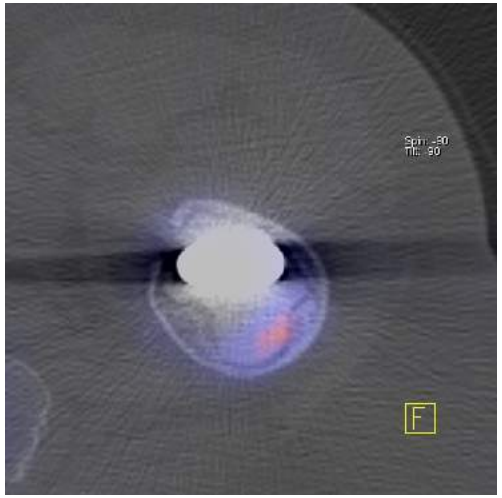

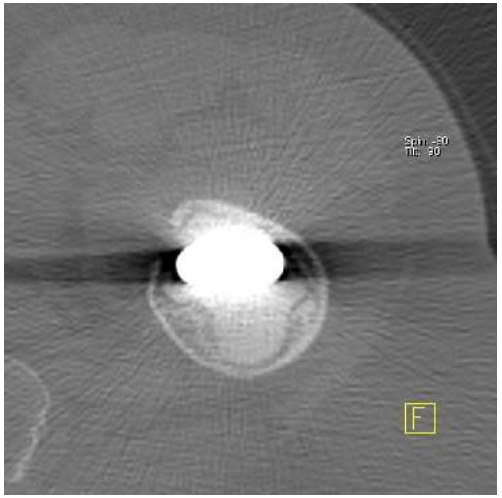

Hüftprothetik – Case 2

Lockerung ? Links? Rechts?

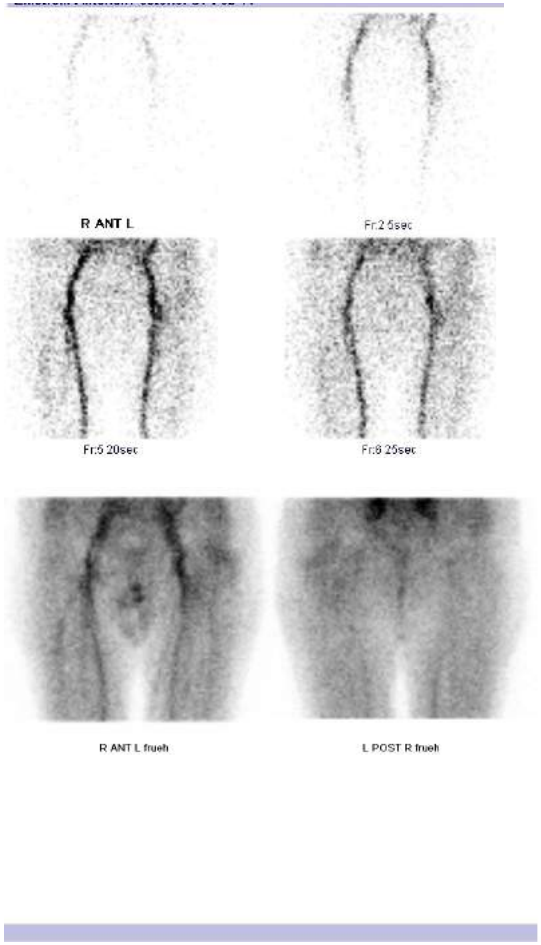

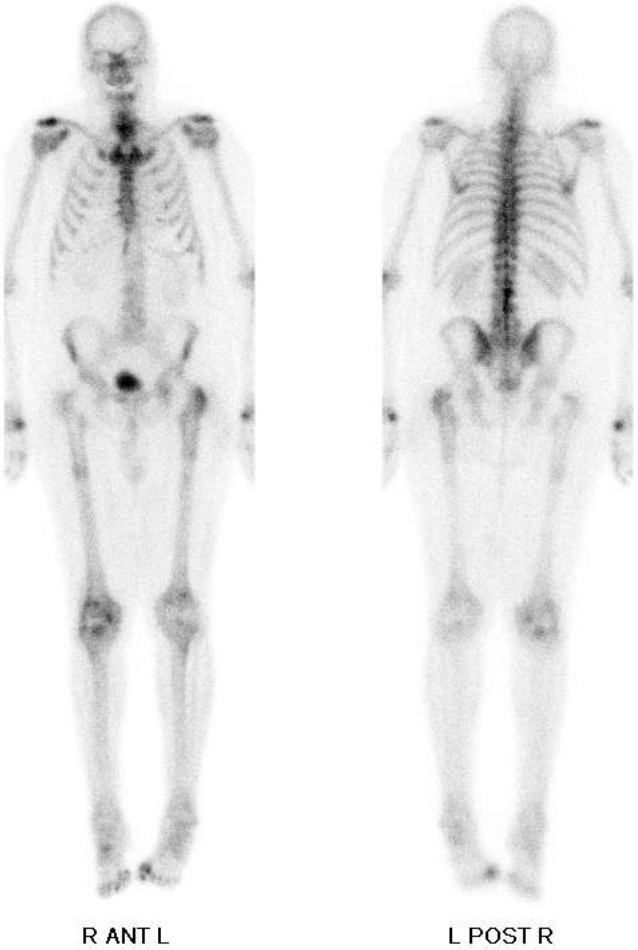

Hüftprothetik -2

Lockerung links! - Rechts Lockerung?

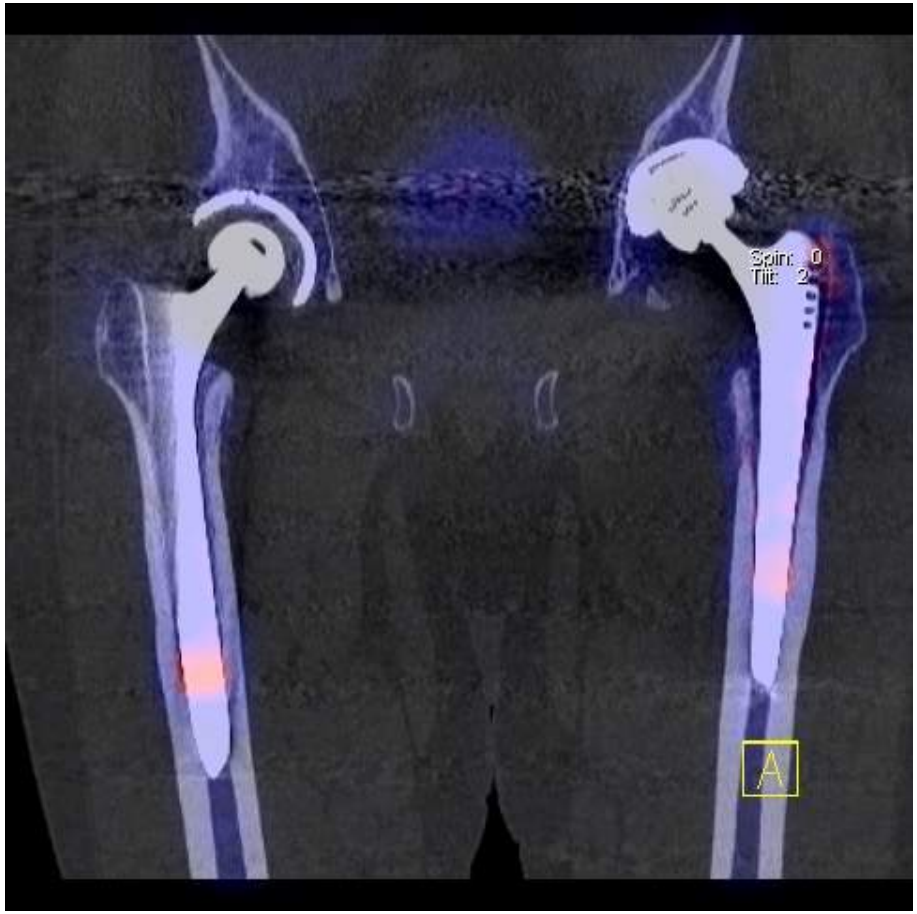

Hüftprothetik

Biomechanik hilft – Wo darf es „leuchten“?

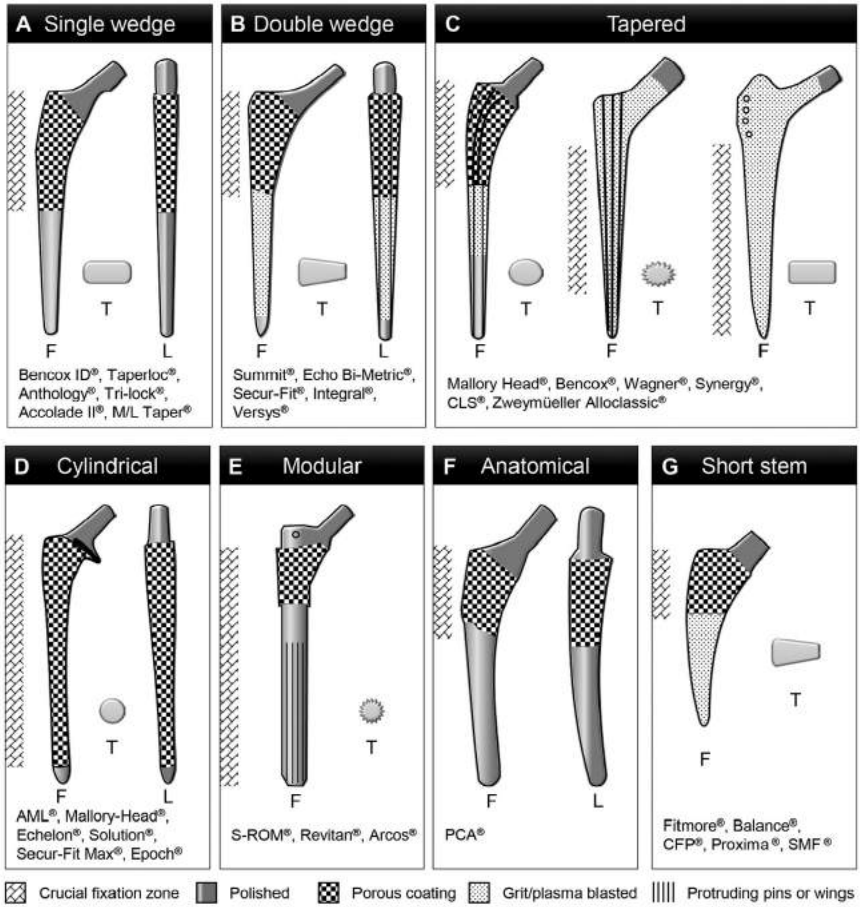

Fixation Wo?

Morphologie beachten

1.Wyngaert, T. V. den *et al.* SPECT/CT in Postoperative Painful Hip Arthroplasty. *Semin Nucl Med* **48**, 425–438 (2018).
With Permission Eldevier, CCC RightsLink

Hüftprothetik Case 3

Kein Uptake - Alles OK?

- HTP rechts 1999
- Schmerzen nach dem Aufstehen
- Druckschmerz inguinal rechts
- Iliopsoasschmerz

Hüftprothetik Case 3

Kein Uptake - Alles OK?

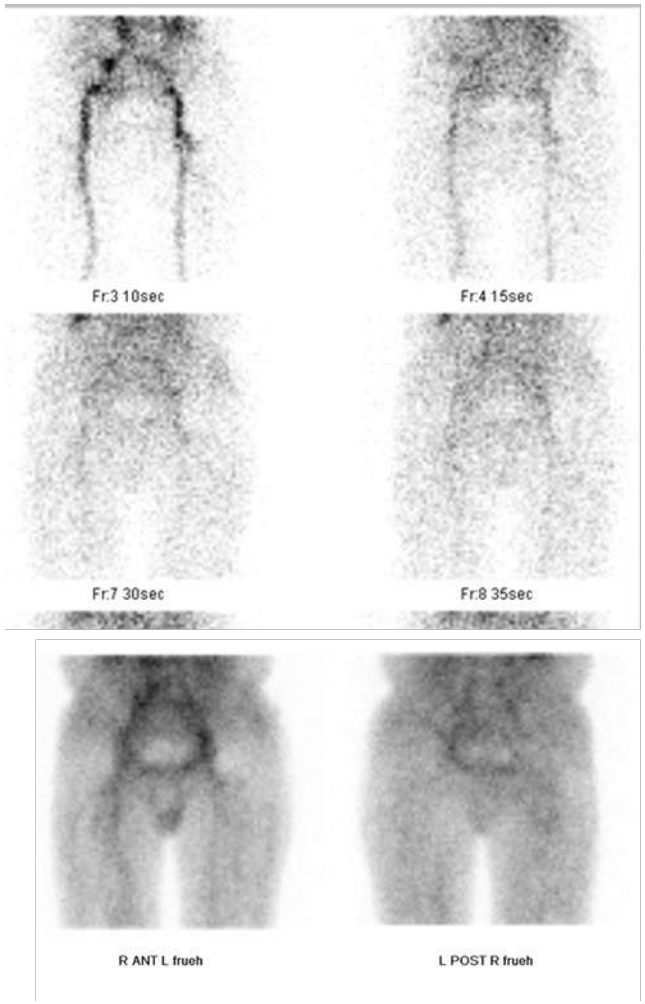

Hüftprothetik Case 3

Riesengranulom - frakturiert

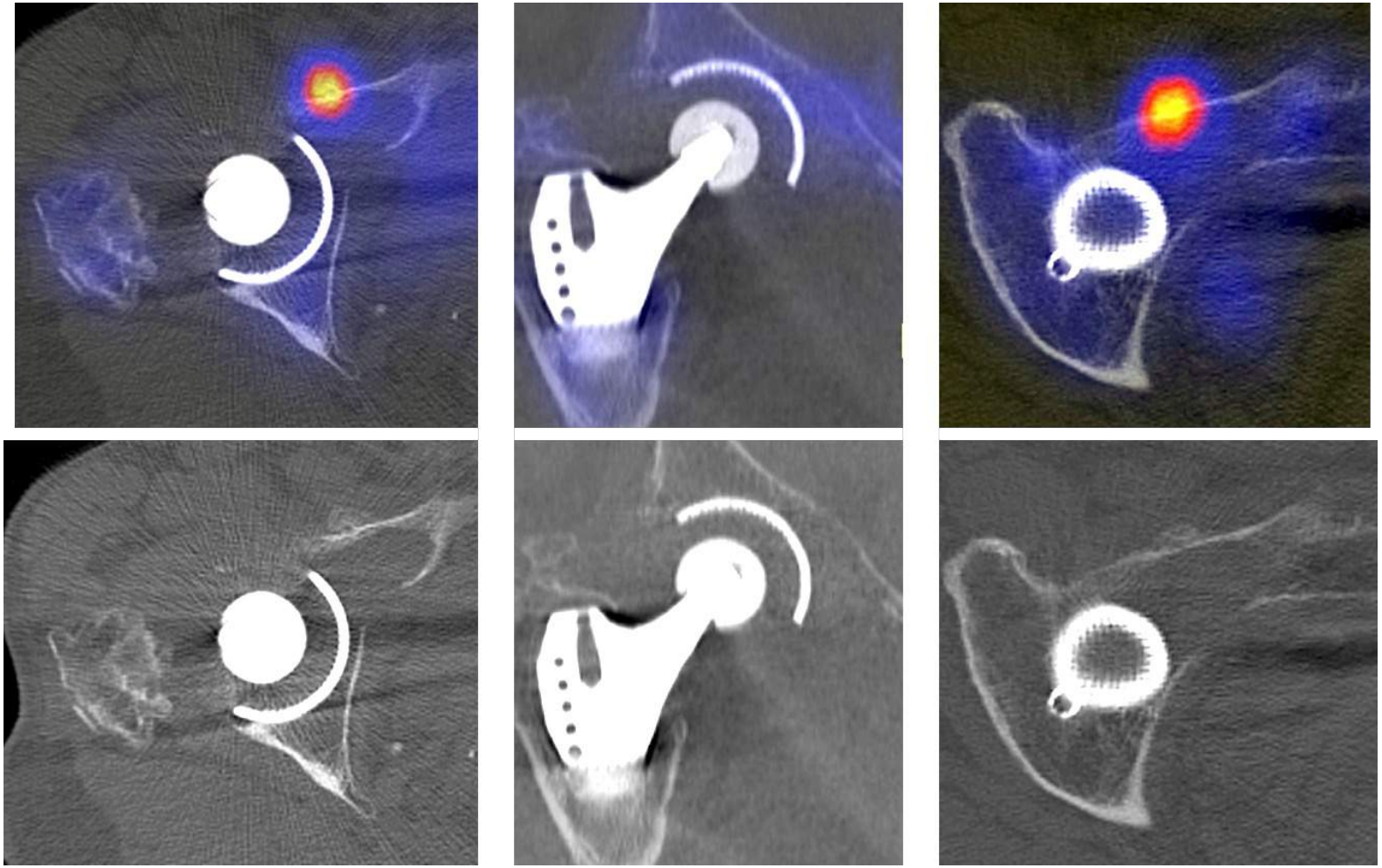

Hüftprothetik Case 4

Lockerung nach Sturz?

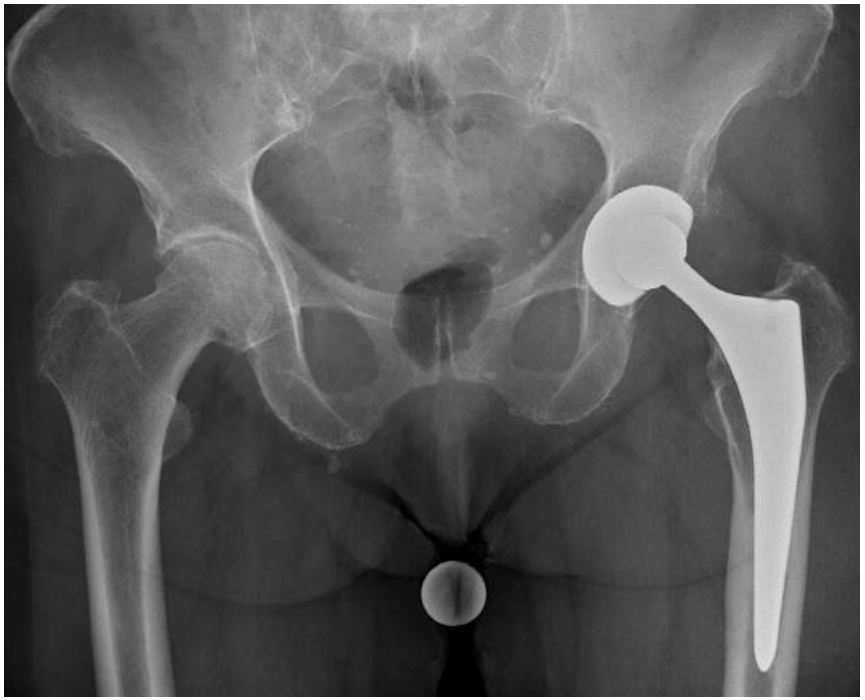

Radiologisch unauffällig – kann nach Hause

Hüftprothetik Case 4

2 Wochen später Beschwerden persistieren

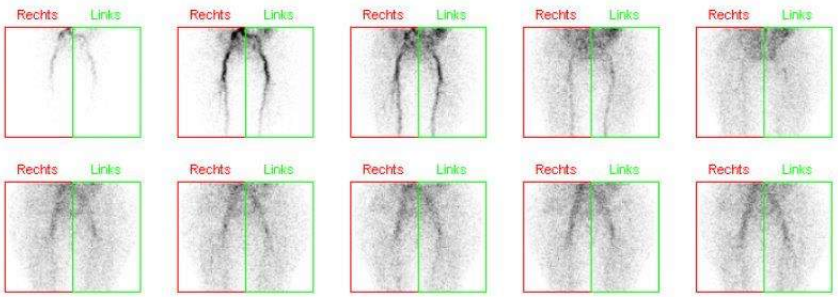

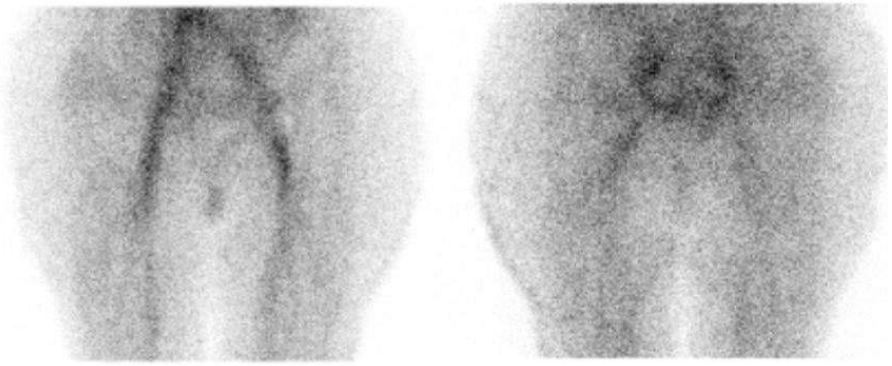

R ANT L frueh

L POST R frueh

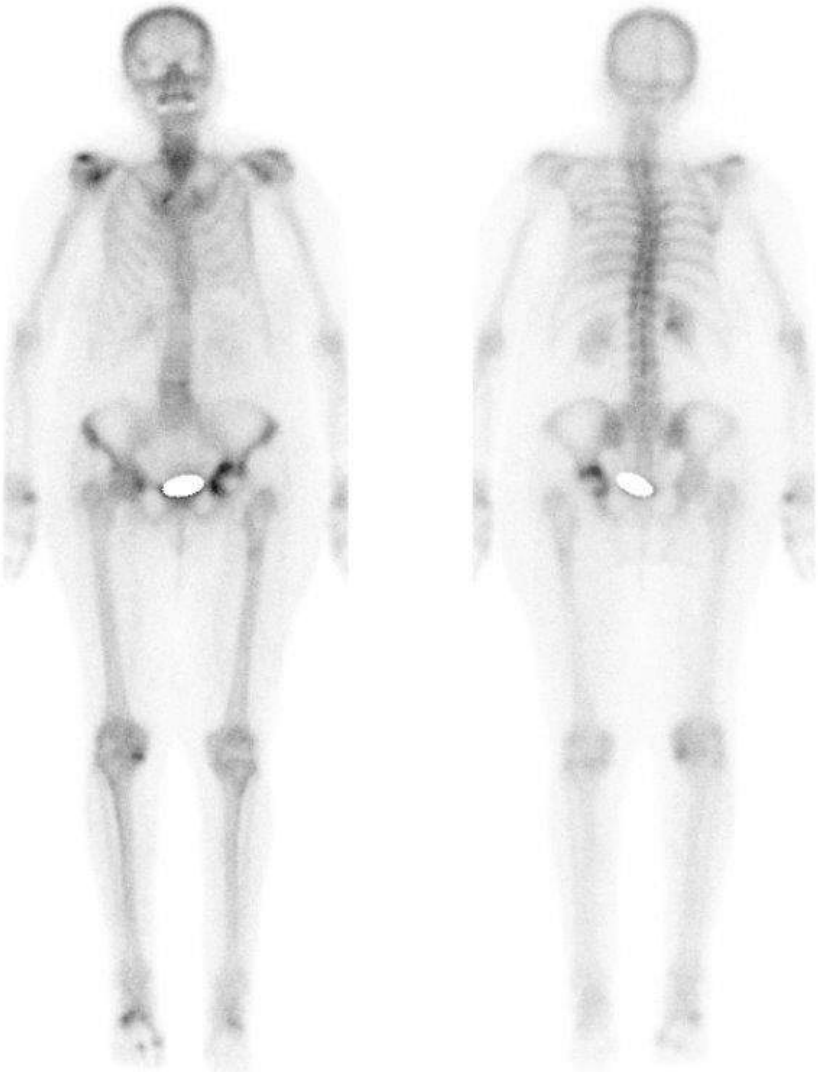

Hüftprothetik Case 4

Traumatische Lockerung und Fraktur – entscheidend für OP Plannung!

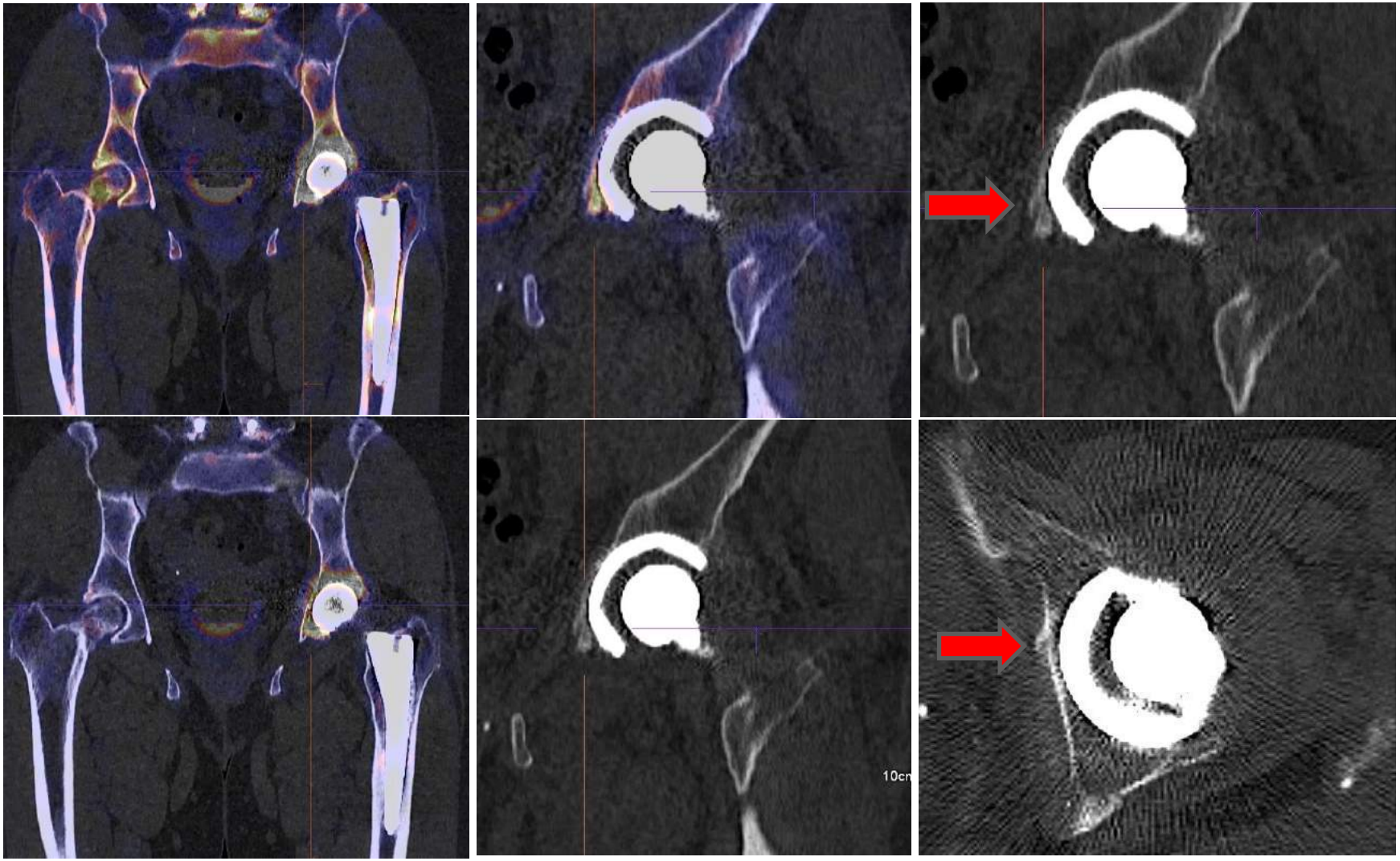

Hüftprothetik Case 5

Weichteilprobleme – genaue Loklisation entscheidend

A

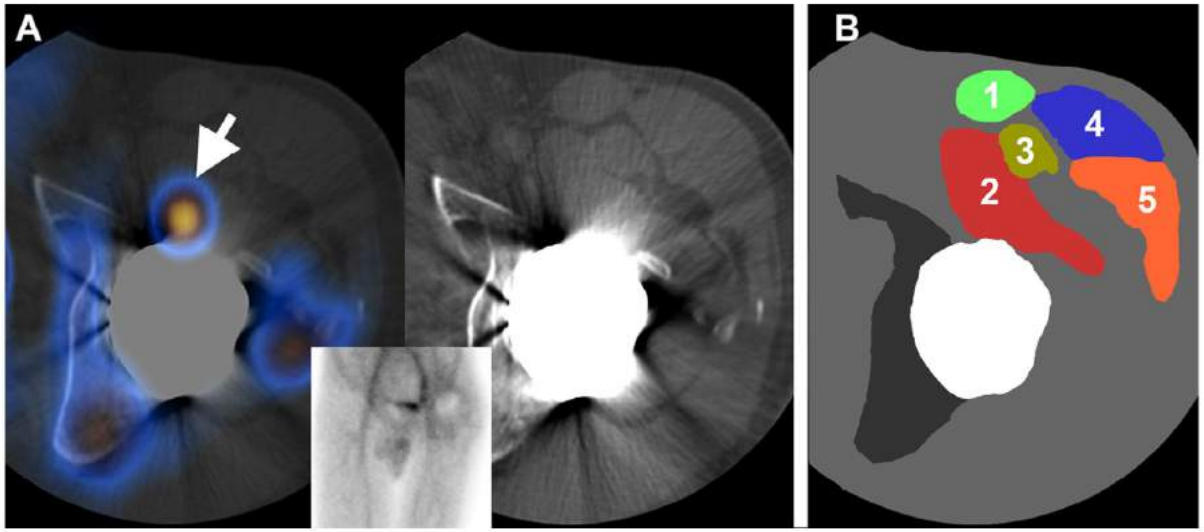

A: Wyngaert, T. V. den *et al.* SPECT/CT in Postoperative Painful Hip Arthroplasty. *Semin Nucl Med* **48**, 425-438 (2018).

With Permission Eldevier, CCC RightsLink

B

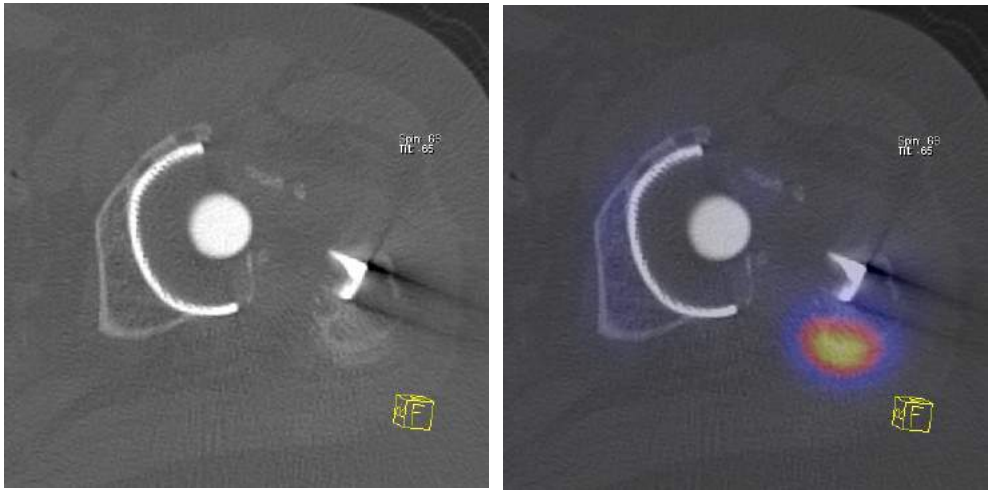

Hüftprothetik

Literatur - Benefit SPECT-CT

Table 2 Best Evidence Overview of Studies Using Bone SPECT/CT After Hip Arthroplasty

Author (Year)	N	Key Finding and Comparator Technique
Studies on standardized reporting and quantification thresholds		
Barthassat et al. (2017)[38]	37	Validation of standardized localization scheme of bone tracer uptake surrounding THAs, which could be grouped to three clinically relevant regions: proximal femur, the distal femur, and the acetabular cup regions.
Jin et al. (2016)[39]	N/A	Identification of ratios of tracer uptake in the femoral and acetabular component to distinguish normal osteoblastic activity from pathologic bone turnover.
Studies on diagnostic accuracy and impact on management		
Schweizer et al. (2017)[37]	58	Bone SPECT/CT identified the cause of pain in 61% of studied THAs.
Trevail et al. (2016)[40]	221	Using an algorithm including bone scintigraphy and labeled white blood cell scan with or without bone marrow scintigraphy, periprosthetic joint infection of THAs could be diagnosed with an accuracy of 97.7%, specificity of 99.5%, and sensitivity of 80%. However, not all included patients received SPECT/CT.
Arican et al. (2015)[41]	20	Compared with planar and SPECT-only imaging, the benefit of SPECT/CT was most pronounced in detecting septic or aseptic loosening in the acetabular component, improving sensitivity from 58% to 89%. Specificity could not be estimated due to the lack of true negative studies.
Dobrindt et al. (2015)[32]	23	The true cause for pain recurrence after uncemented THA was identified in 72% of patients with bone SPECT/CT, compared with 50% with SPECT imaging only.
Berber et al. (2015)[42]	15	Bone SPECT/CT changed the management decision in 68% of patients with unexplained hip pain after metal-on-metal THA. Interestingly, nonhip pathology (ie, predominantly of the spine) was identified in 32% of patients.
Studies on bone SPECT/CT to assess bone viability		
Diederichs et al. (2017)[43]	56	Bone SPECT/CT has a high sensitivity (90%) and specificity (94%) to distinguish viable and nonviable bone tissue in patients after girdlestone arthroplasty.
Kilicarslan et al. (2017)[44]	9	Preliminary data suggest that bone SPECT/CT can be used to assess the viability of bone allografts when used to fill large acetabular defects in revision total hip arthroplasty.
Han et al. (2017)[45]	53	Postoperative bone SPECT/CT has excellent negative predictive value to rule out avascular necrosis of the femoral head after internal fixation of a femoral neck fracture. However, the specificity of cold defects 2 weeks after surgery is very low, with many patients showing normalization of uptake on follow-up studies in the months following surgery.
Fontecha et al. (2016)[46]	10	Initial experience shows that bone SPECT/CT at 2 wk and 6 mo following free vascularized fibular grafting surgery for osteonecrosis of the femoral head can visualize subchondral graft bone viability.

THAs, total hip arthroplasties.

Reporting

Accuracy
Patienten Managment

Wyngaert, T. V. den *et al.* SPECT/CT in Postoperative Painful Hip Arthroplasty. *Semin Nucl Med* **48**, 425-438 (2018).

Kantonsspital Baselland

KNIEPROTHETIK

SPECT-CT

Biology und Biomechanik

Clin Orthop Relat Res (2014) 472:212–217
DOI 10.1007/s11999-013-3111-7

Clinical Orthopaedics and Related Research®

SYMPOSIUM: 2013 KNEE SOCIETY PROCEEDINGS

Inter- and Intraobserver Reliability of Two-dimensional CT Scan for Total Knee Arthroplasty Component Malrotation

Beau Konigsberg MD, Ryan Hess MD,
Curtis Hartman MD, Lynette Smith MS,
Kevin L. Garvin MD

Published online: 28 June 2013

Abstract

Background Rotational malalignment of total knee arthroplasty (TKA) has been correlated with patellofemoral maltracking, knee instability, and stiffness. CT is the most accurate method to assess rotational alignment of prosthetic components after TKA, but inter- and intraobserver reliability of CT scans for this use has not been well documented.

Questions/purposes The objective of this study was to determine the inter- and intraobserver reliability and the repeatability of the measurement of TKA component rotation using two-dimensional CT scans.

Methods Fifty-two CT scans of TKAs being evaluated for revision surgery were measured by three different physicians. An orthopaedic resident and attending measured the same scans twice (more than 2 weeks apart) and a musculoskeletal radiologist measured them once. To assess interobserver reliability, intraclass correlation coefficients (ICCs) with two-way mixed-effects analysis of variance models as well as 95% confidence intervals for each were done. The repeatability coefficient was calculated as well, which is defined as the difference in measurements that include 95% of the values. This indicates the magnitude of variability among measurements in the same scale, which in this study is degrees.

Results The interobserver ICC measurement for the femoral component was 0.386 (poor), and it was 0.670 (good) for the tibial component. The interobserver ICC for the combined rotation measurements was 0.617 (good). The intraobserver ICC for the femoral component was 0.606 (good), and it was 0.809 (very good) for the tibial component. The intraobserver ICC for combined rotation was 0.751 (good). The intraobserver repeatability coefficient for the femoral component was 0.49°, 10.64° for the tibial component, and 12.29° for combined rotation.

Conclusions In this study, the inter- and intraobserver reliability, and the repeatability, of TKA component rotation were variable. This raises concern about whether CT scan is diagnostic in the assessment of component malrotation after TKA.

Level of Evidence Level IV, diagnostic study. See Guidelines for Authors for a complete description of levels of evidence.

One or more of the authors (CH, KLG) have received funding that is not related to the content of this manuscript. The funding source includes Biomet (Warsaw, IN, USA) (KLG) in the amount of USD 100,000 to USD 1,000,000 and Smith & Nephew (Memphis, TN, USA) (CH) in the amount of USD 10,000 to USD 100,000. The institution of the authors has received funding from TRAK Surgical Inc (Omaha, NE, USA), Smith & Nephew, Biomet, Vanguard (Valley Forge, PA, USA), Exponent (Menlo Park, CA, USA), Gruppo Bioimplanti (St Paul, MN, USA), and Renovis (Redlands, CA, USA). All ICMJE Conflict of Interest Forms for authors and *Clinical Orthopaedics and Related Research* editors and board members are on file with the publication and can be viewed on request.
Each author certifies that his or her institution approved the human protocol for this investigation, that all investigations were conducted in conformity with ethical principles of research, and that informed consent for participation in the study was obtained.

B. Konigsberg, R. Hess, C. Hartman, L. Smith,
K. L. Garvin (✉)
University of Nebraska Medical Center,
Omaha, NE 68198-1080, USA
e-mail: kgarvin@unmc.edu

Introduction

The majority of patients undergoing TKA have excellent clinical results [14, 18, 19, 21]. A minority of patients may experience knee pain, stiffness, and/or patellar instability

47

1998

Malrotation causing patellofemoral complications after total knee arthroplasty.

- stiffness
- knee pain
- patella instability

2006

Internal rotation > 5° can cause patellofemoral problems

- abnormal patellar tracking
- PE wear
- anterior knee pain

2011

Benefit of revision to correct malrotation of TKR

- Improved pain scores and Knee society scores
- Better range of motion (ROM)

2013

2D Rotational measurment using CT:

- Problem of inter- and intraobserver reliability
- „This raises concern about whether CT scan is diagnostic in the assessment of component malrotation after TKA“

SPECT-CT

Biomechanik in 3 D

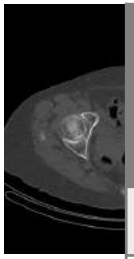



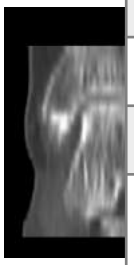

	ICC intraobserver	ICC interobserver
Femoral		
Varus -Valgus	0,99	0,99
Flexion-extension	0,97	0,99
Internal-external rotation	0,92	0,85
Tibial		
Varus-Valgus	0,98	0,98
Slope	0,99	0,99
Internal-external rotation	0,95	0,93

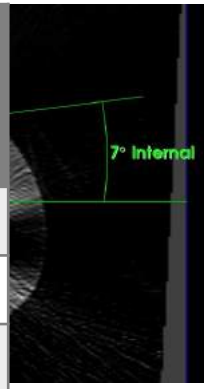

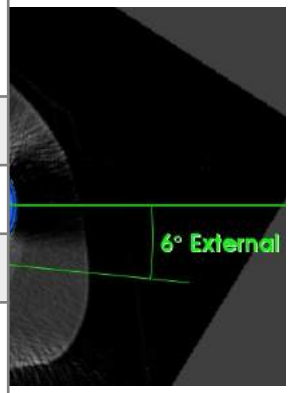

PD Dr. M. Hirschmann et.al

Swiss Quality Award
INNOVATIONS IN HEALTHCARE

Knieprothetik Case1

schmerzhafte Schlittenprothese - Lockerung?

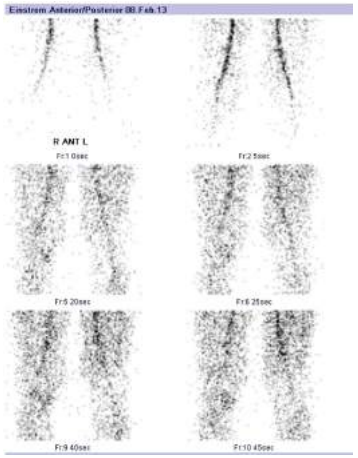

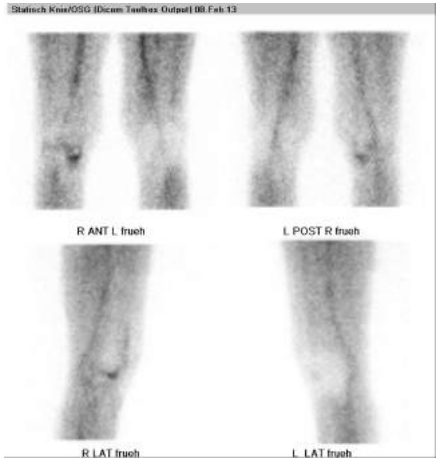

Knieprothetik Case1

schmerzhafte Schlittenprothese - Lockerung?

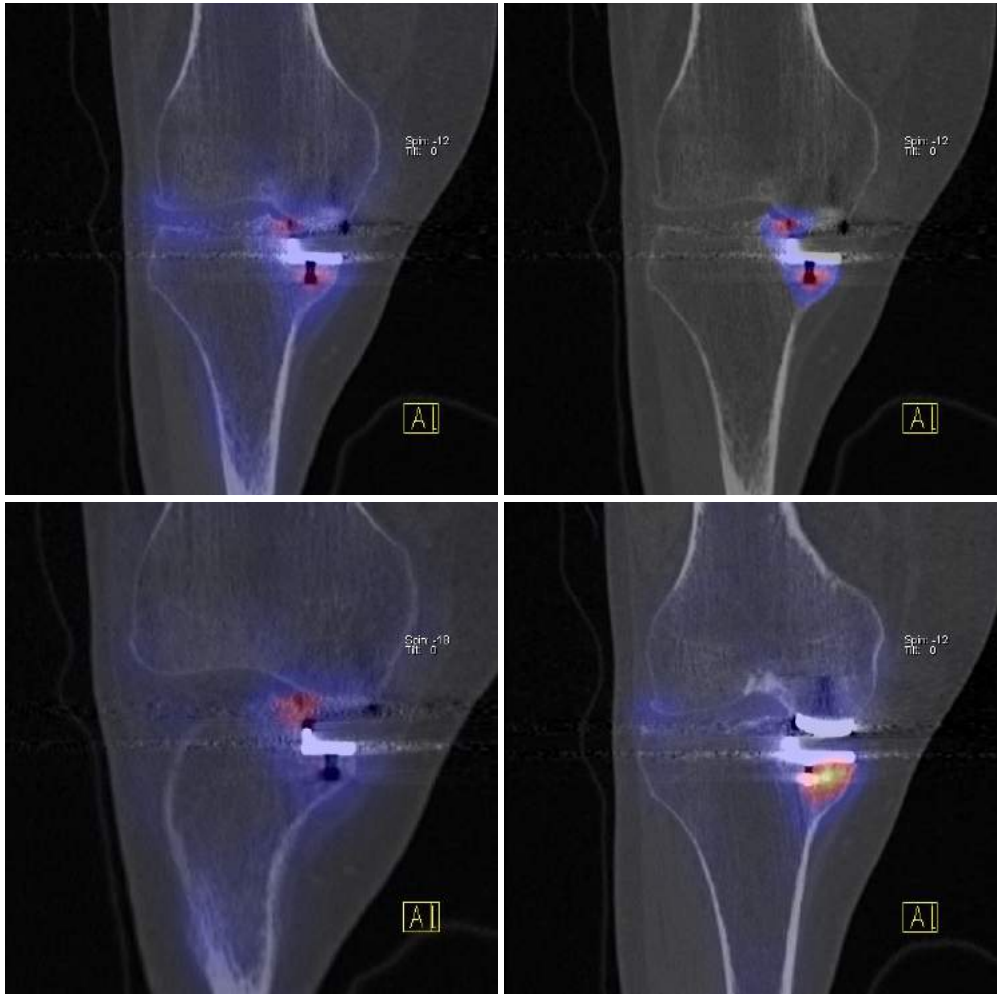

Knieprothetik Case1

schmerzhafte Schlittenprothese - Lockerung?

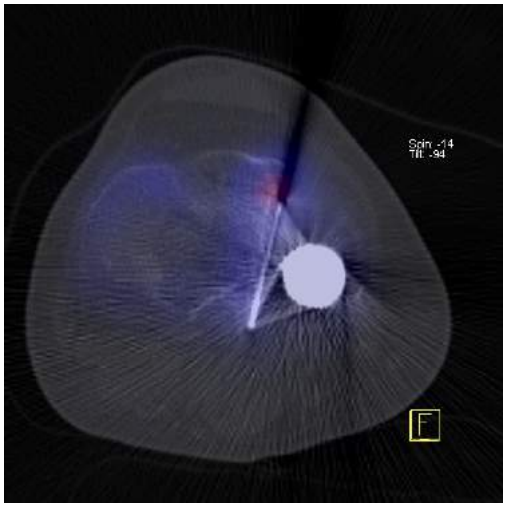

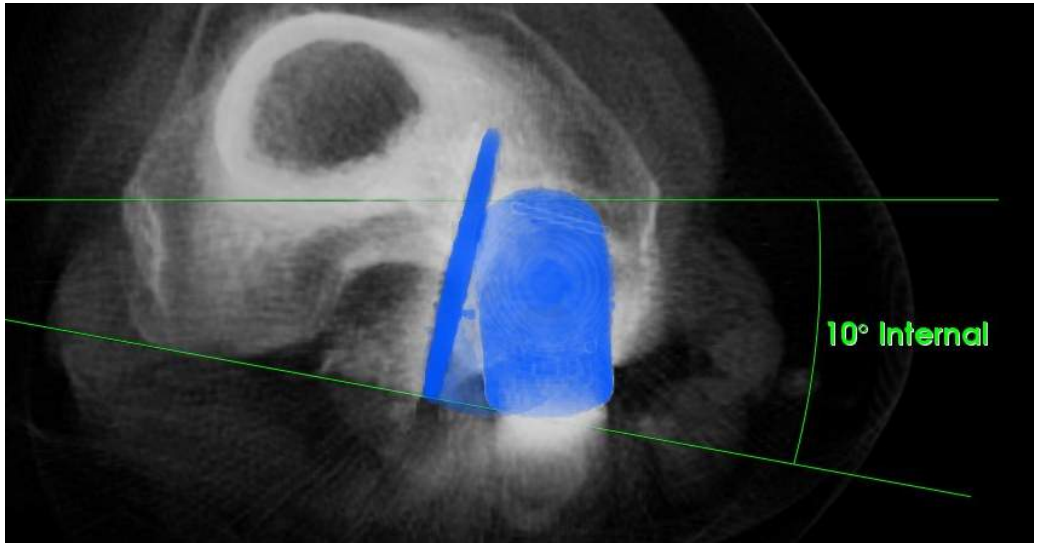

Knieprothetik Case 2

schmerzhafte Schlittenprothese – Lockerung?

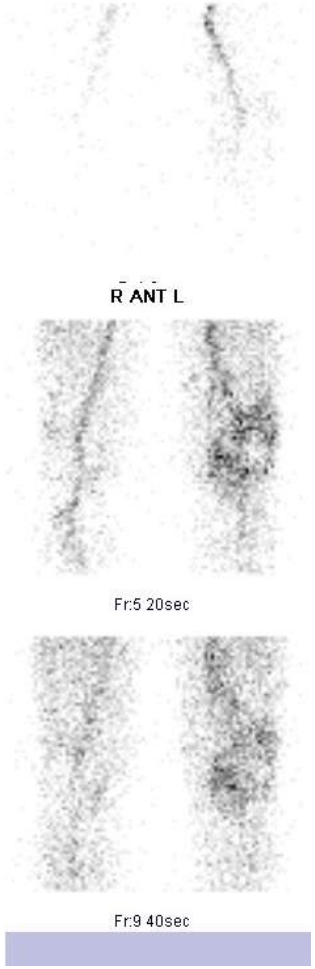

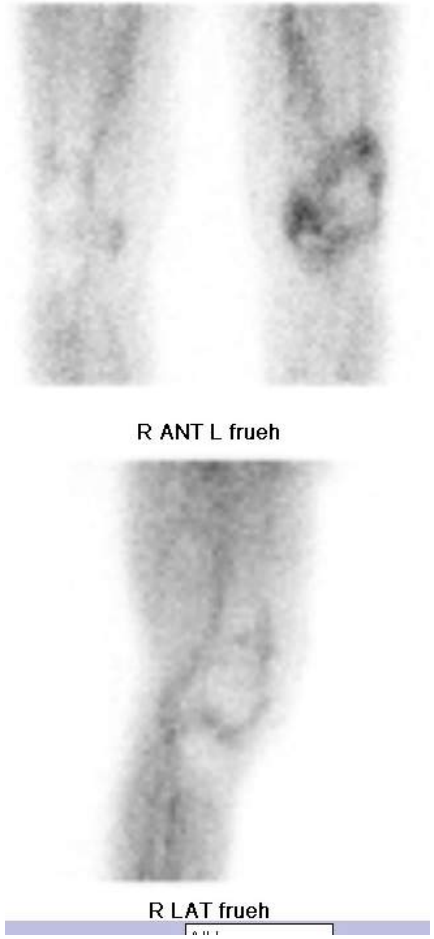

Knieprothetik Case 2

schmerzhafte Schlittenprothese – fem. Lockerung – Granulom
OP Plannung!

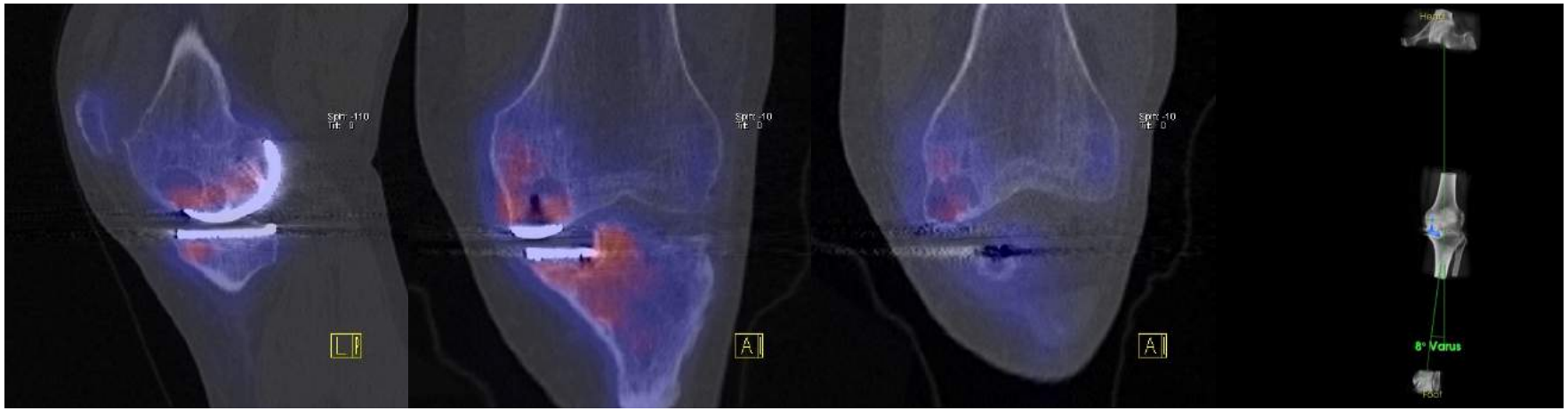

Knieprothetik Case 3

Lockerung? Varusstress

Knieprothetik Case 3

Keine Lockerung aber Varusstress - Komponentenfehllage

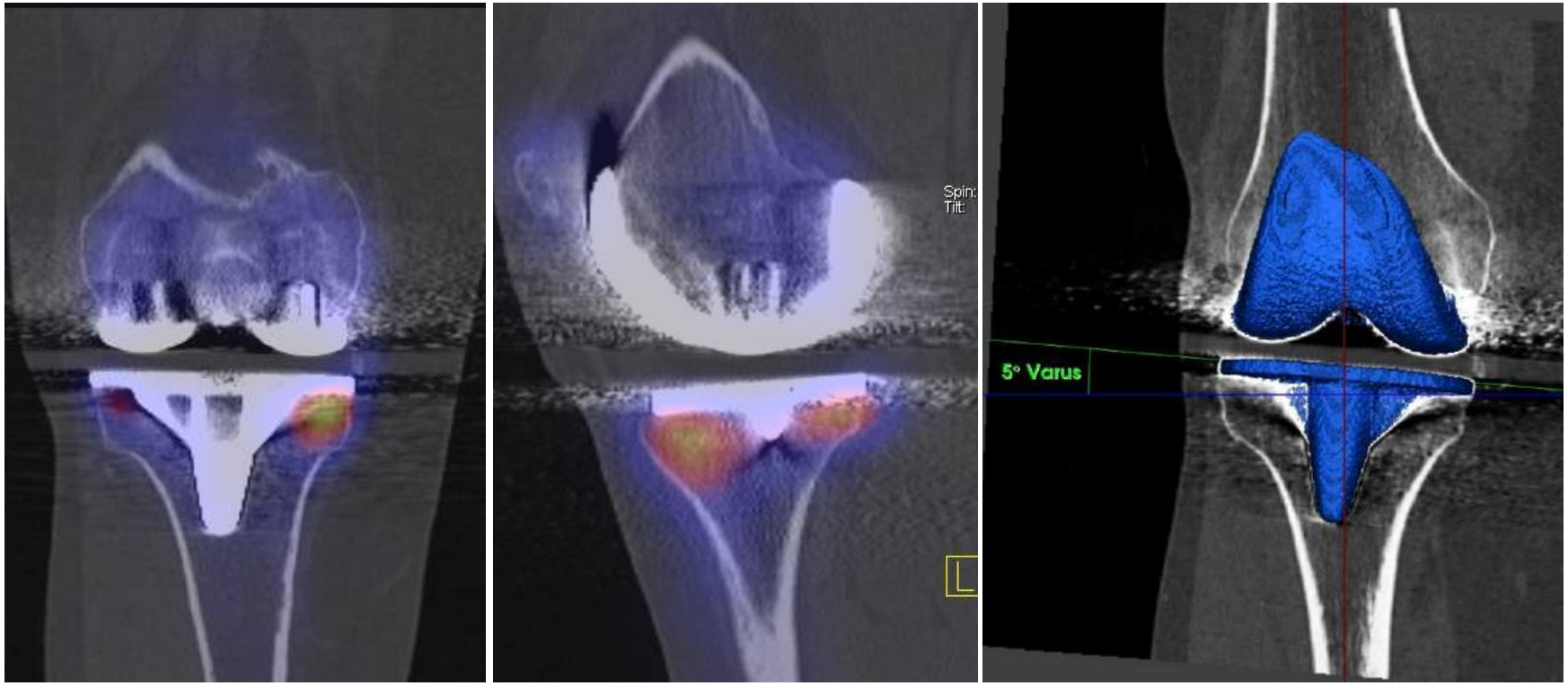

Knieprothetik Case 4

Tibiale Lockerung?

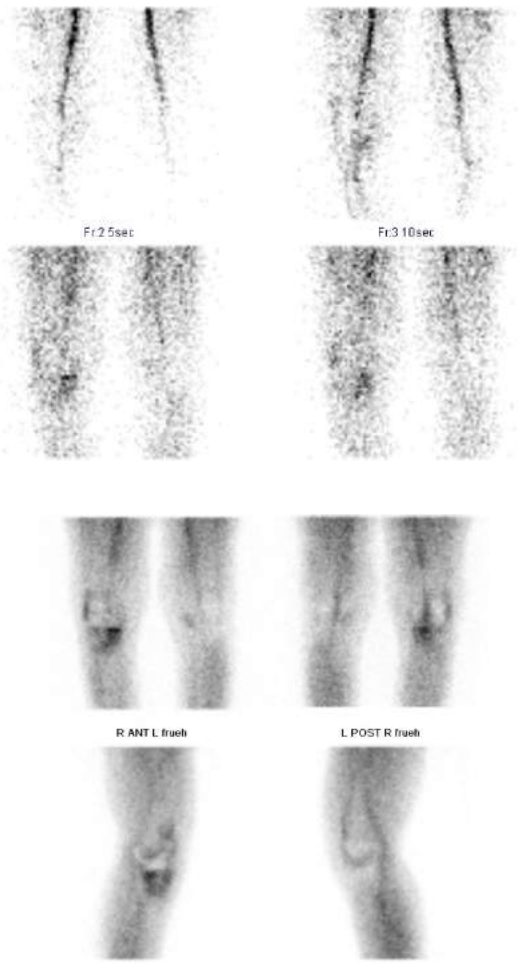

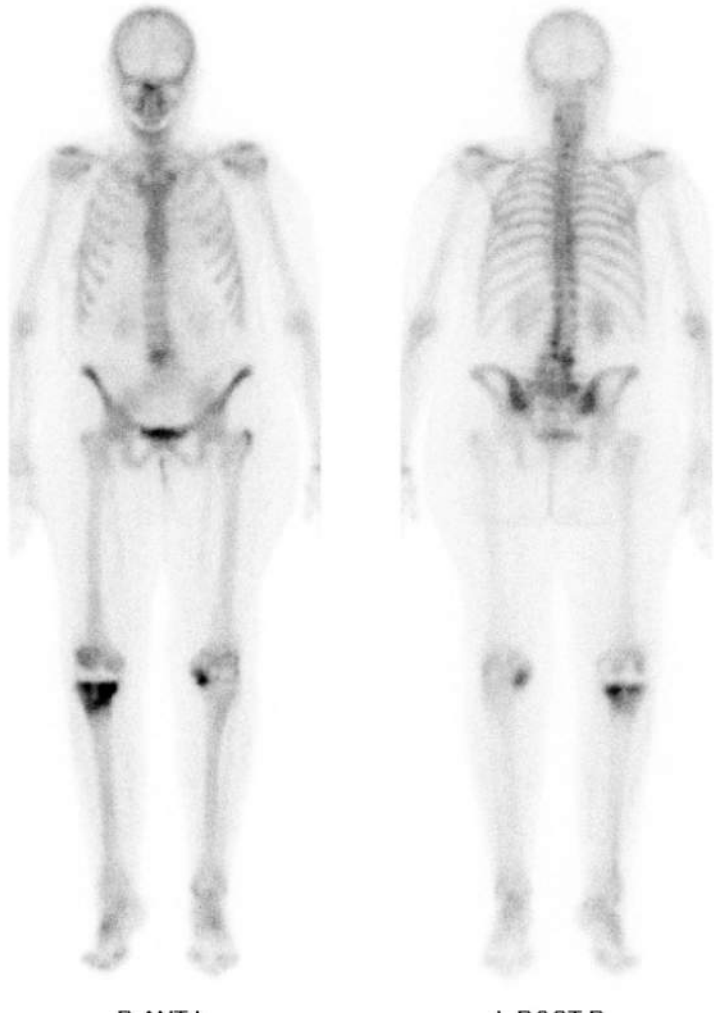

Knieprothetik Case 4

Tibiale Lockerung?

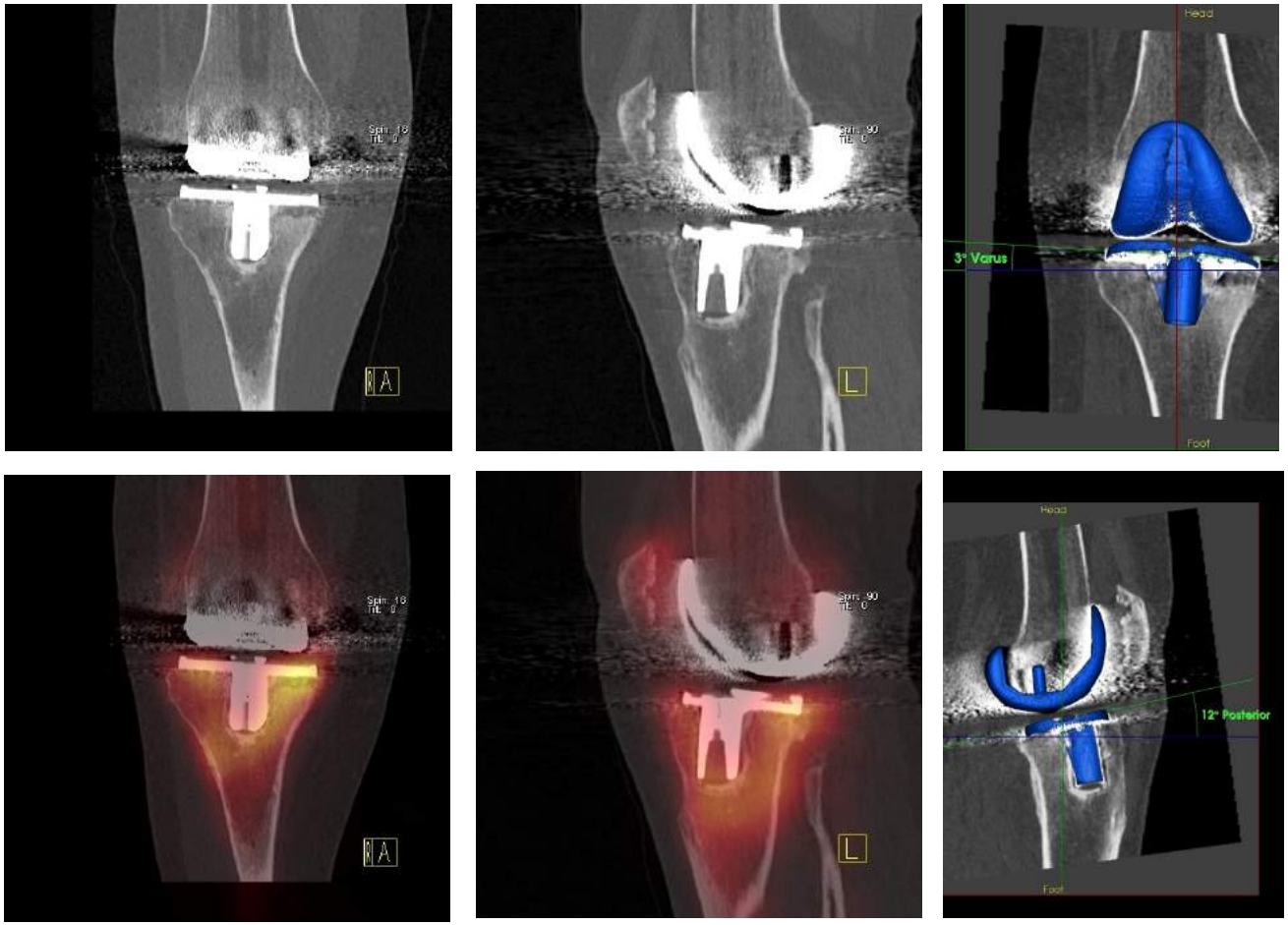

Knieprothetik Case 5

V.a. tibiale Lockerung?

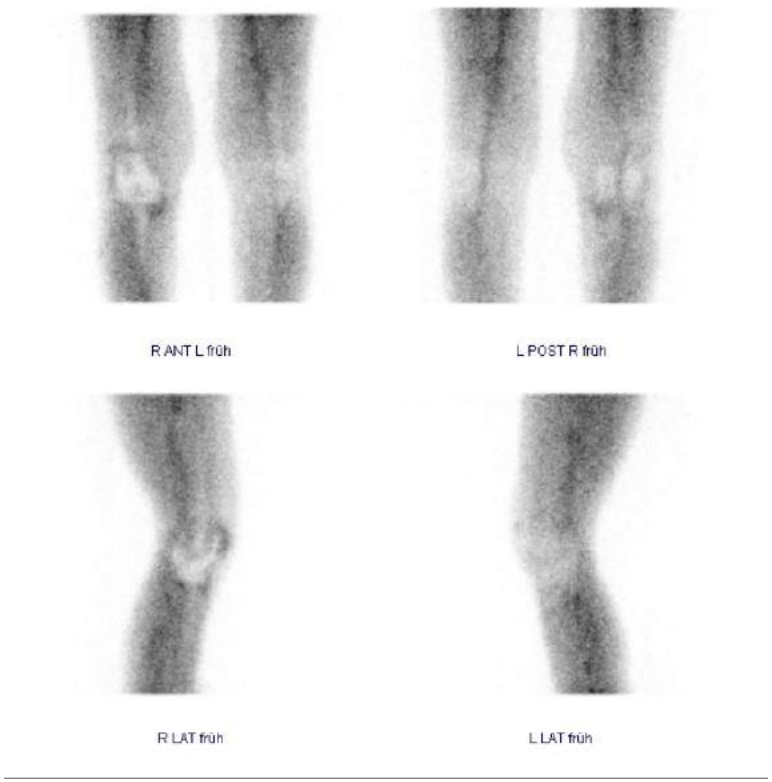

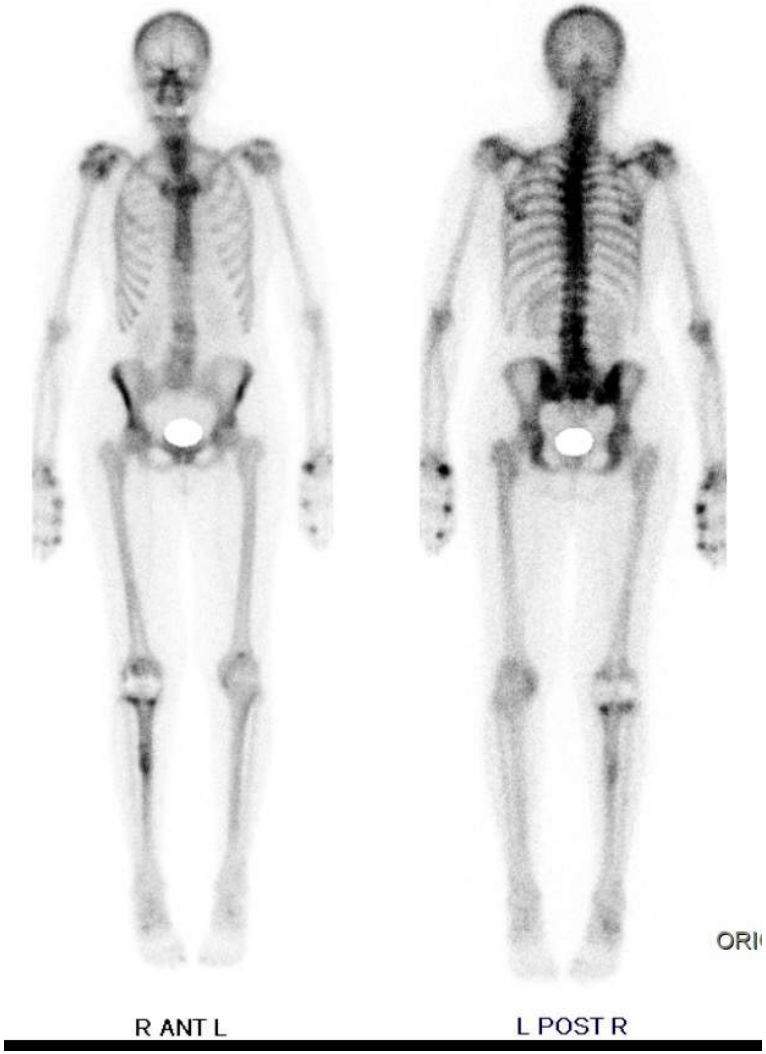

Knieprothetik Case 5

V.a. tibiale Lockerung?

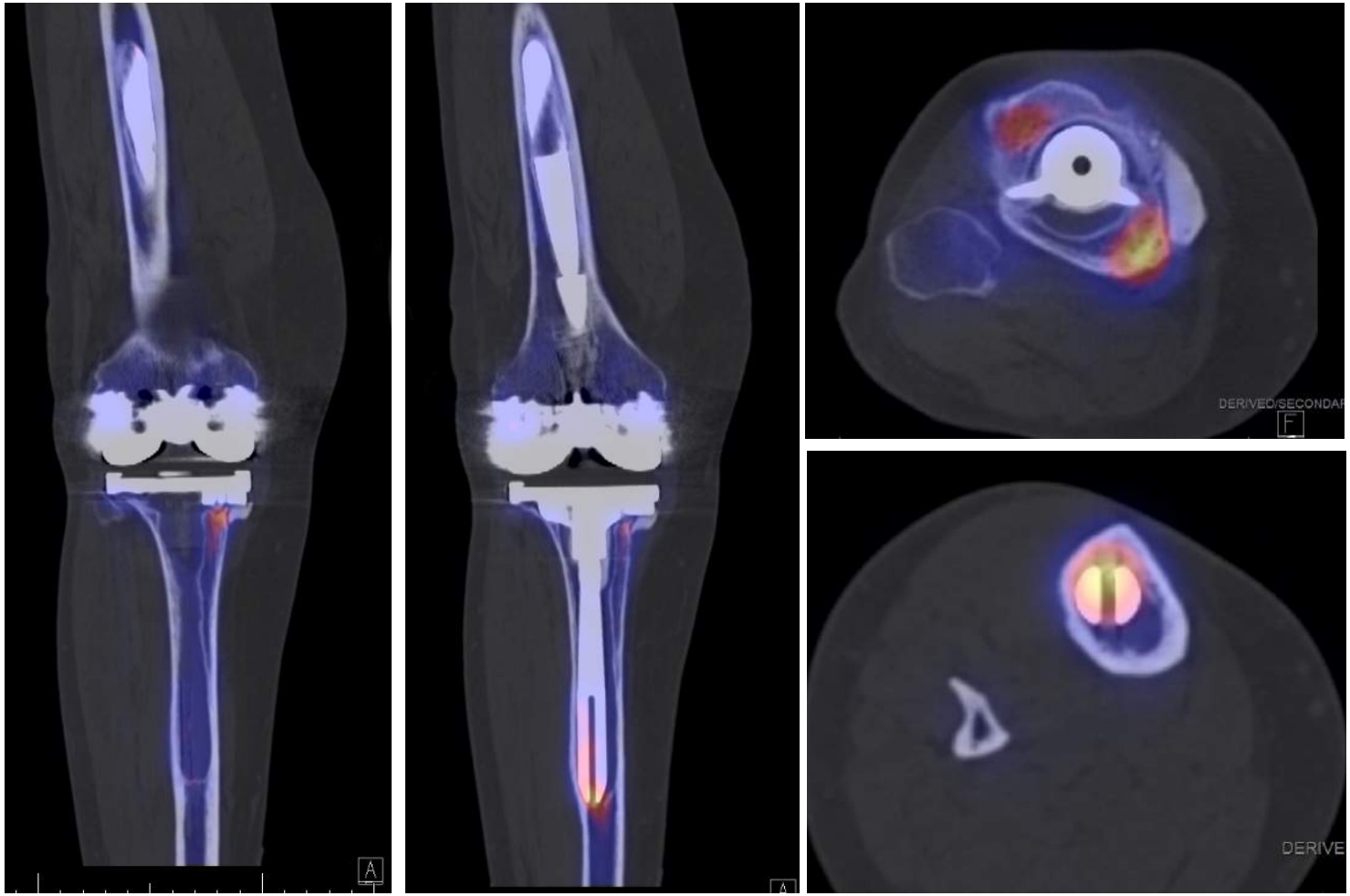

Knieprothetik Case 6

Lockerung Retropatellarersatz? Rotationsfehler!

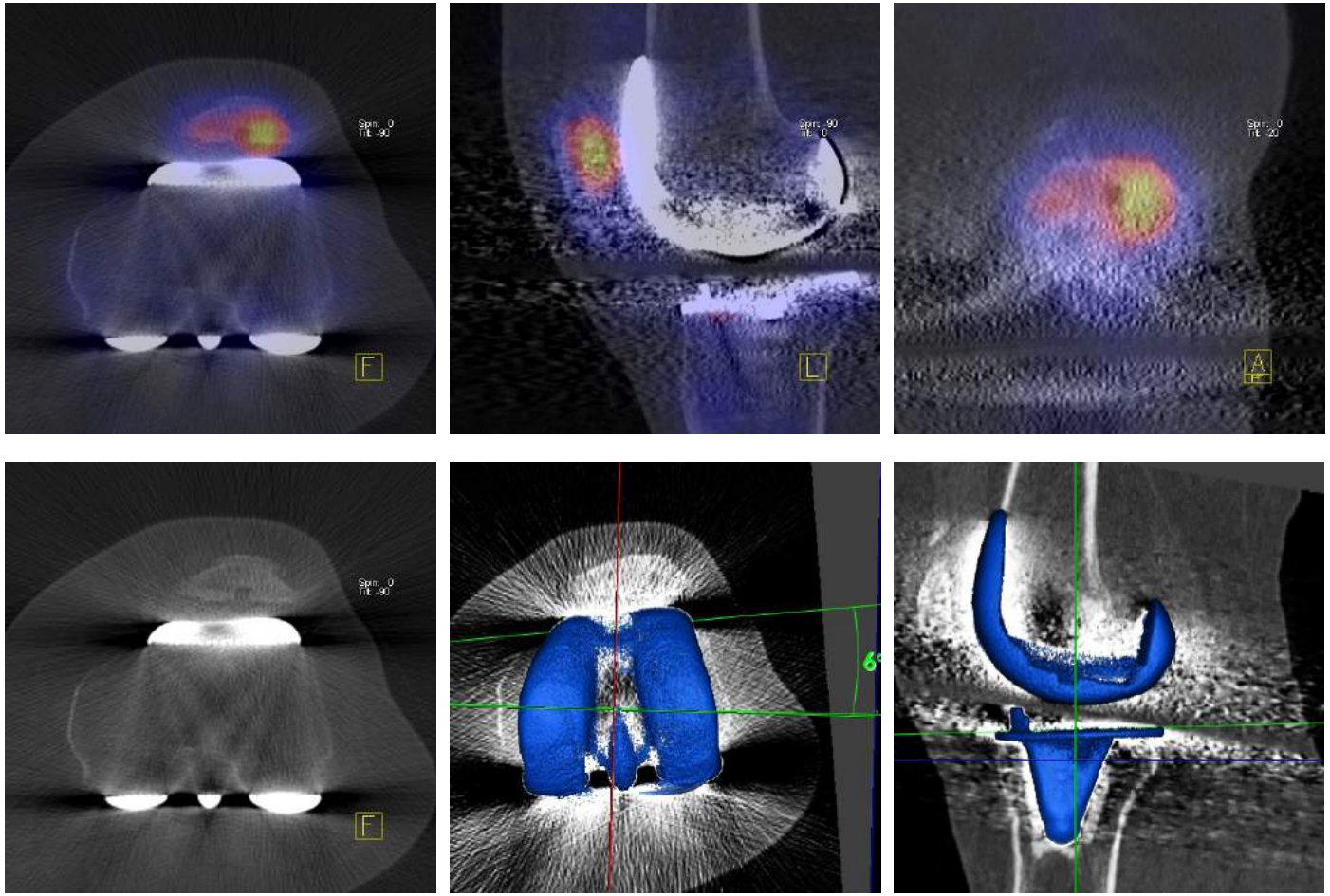

6° InnenRot

2° ant. slope

Knieprothetik Case 7

Z.n. periprothetischer Fraktur femoral mit Osteosynthese
Lockerung? Infekt?

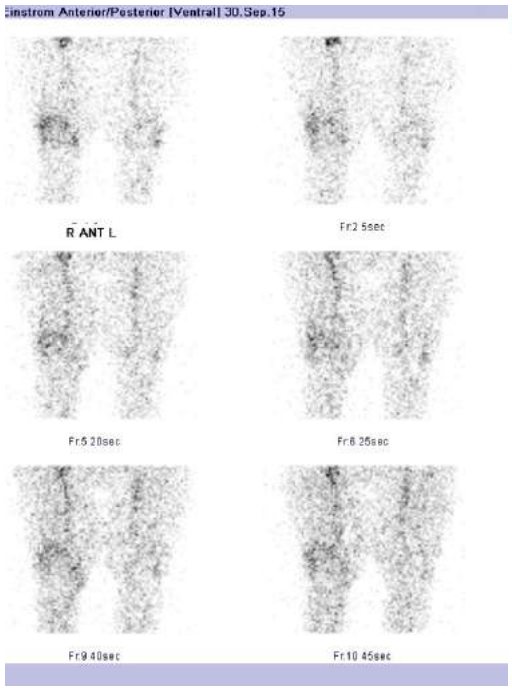

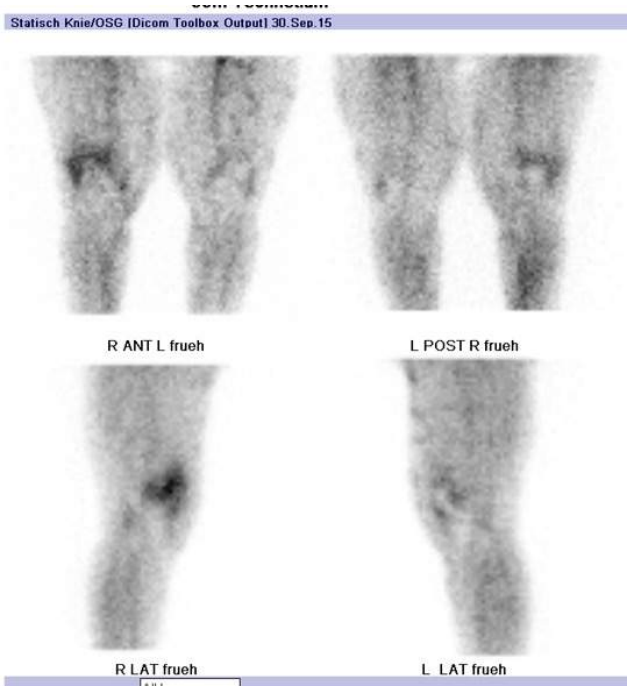

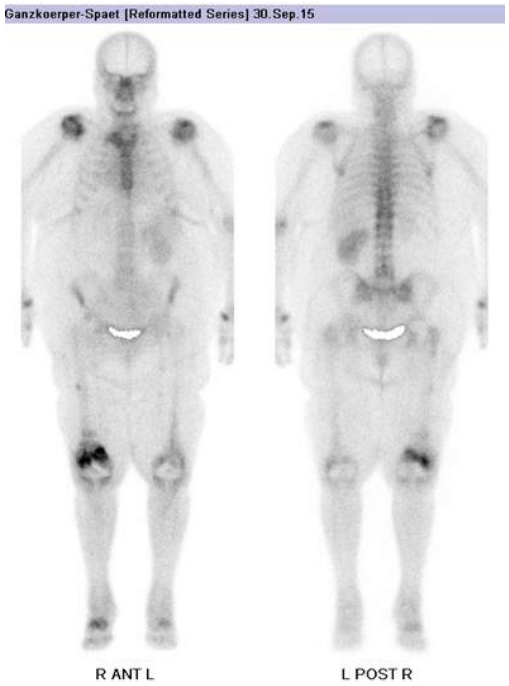

Knieprothetik Case 7

Z.n. periprothetischer Fraktur. Lockerung? Infekt? Patellaimpingment





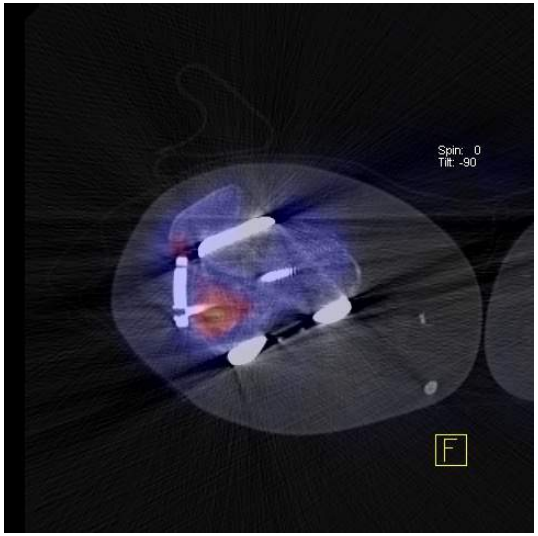

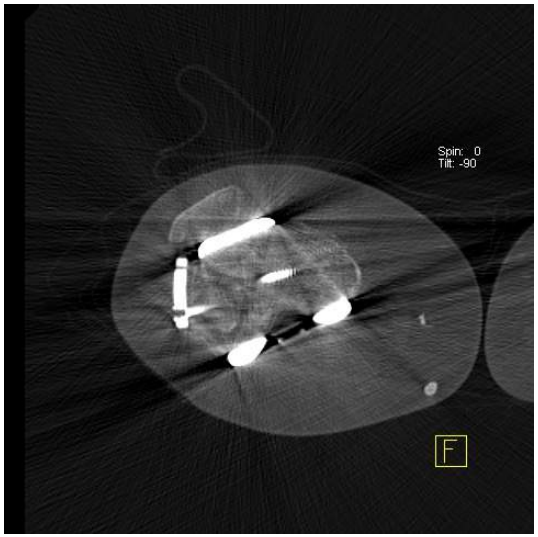

Knieprothetik Case 8

Tibiale Schmerzen - Lockerung?

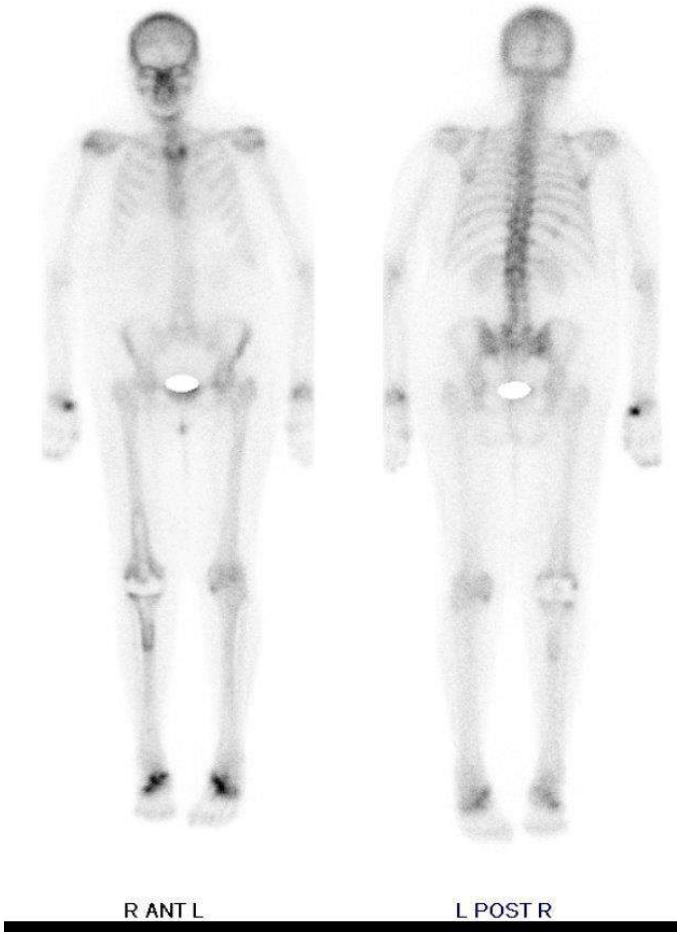

Knieprothetik Case 8

Tibiale Schmerzen – End of Stem Pain

Knieprothetik Case 9

Manchmal ist man „betriebsblind“

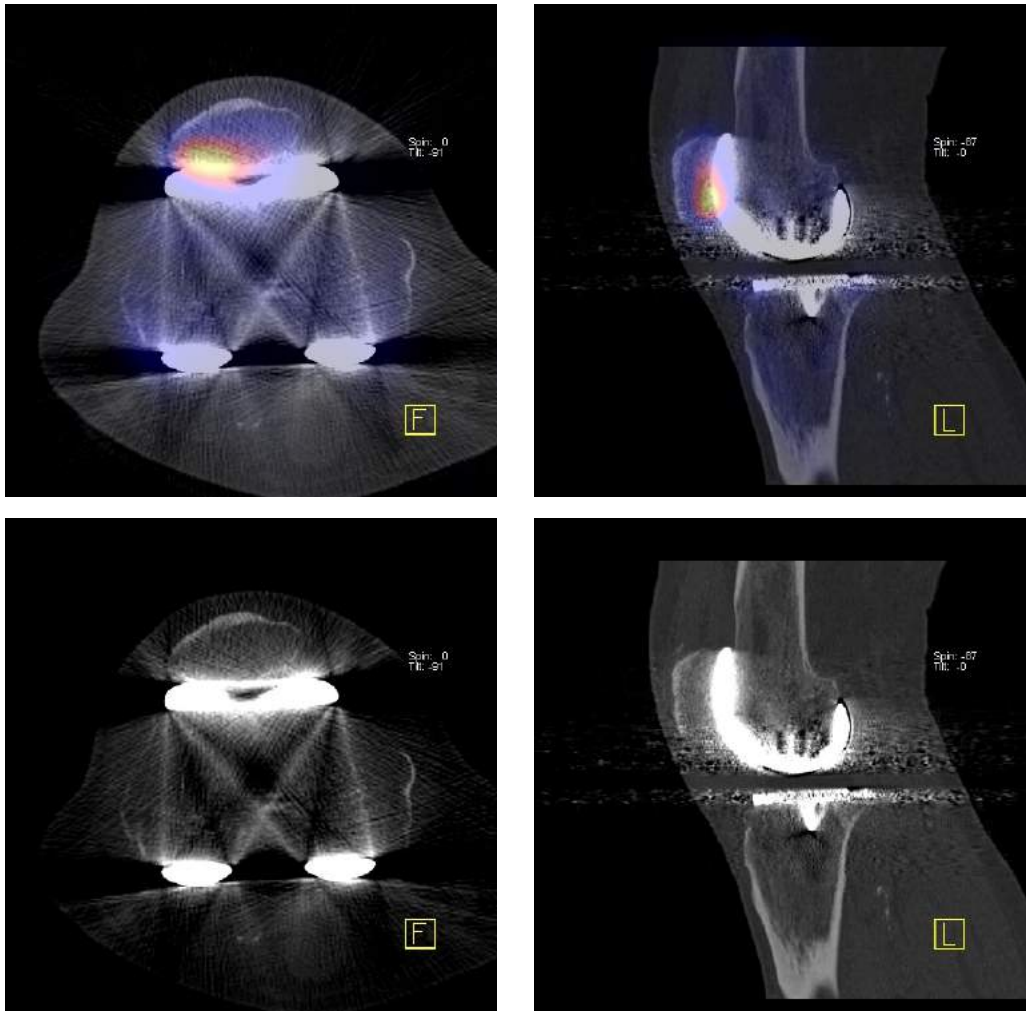

Knieprothetik Case 8

Manchmal ist man „betriebsblind“

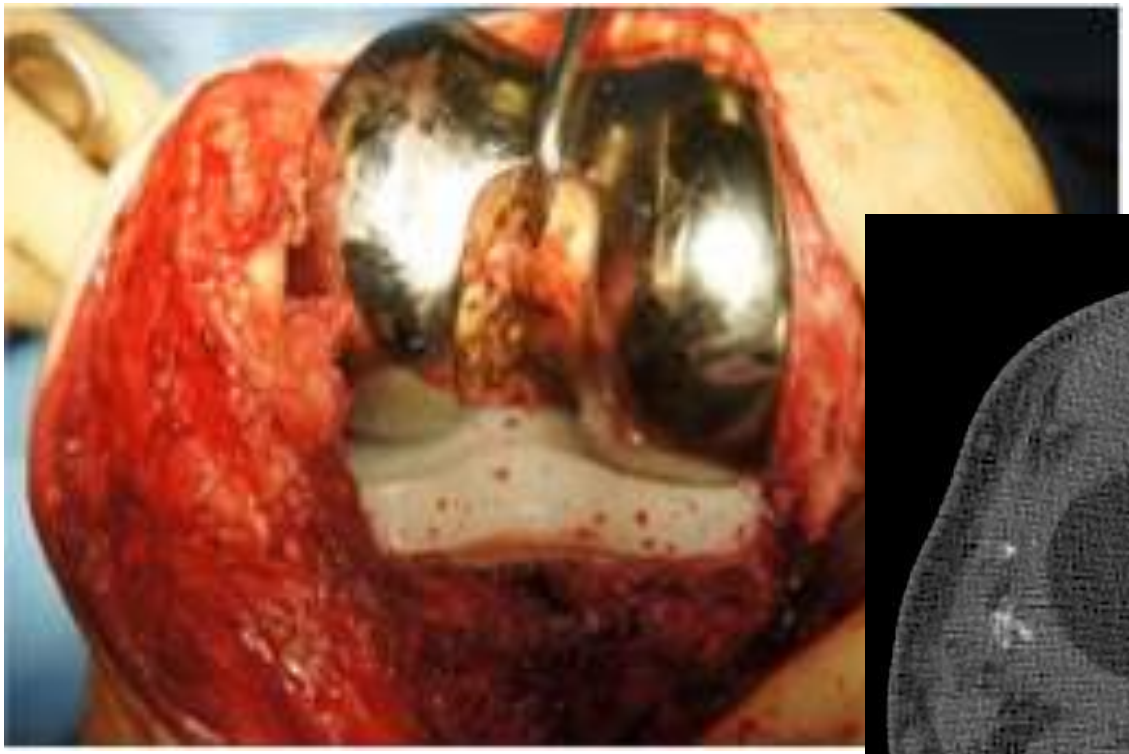

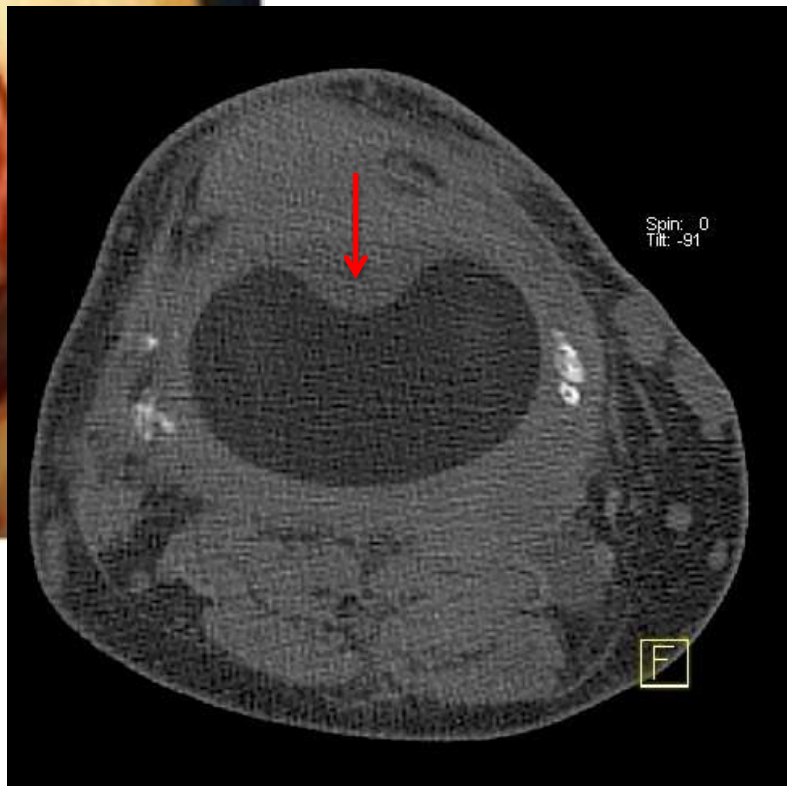

Inlay 180° gedreht

Arthro SPECT-CT

Diagnostic accuracy of SPECT/CT arthrography in patients with suspected aseptic joint prostheses loosening

Bo Bao[1*], Crystal S. Liu[2], Edward C. O. Masson[3] and Jonathan T. Abele[1]

* Correspondence: bbao@ualberta.ca
[1]Department of Radiology and Diagnostic Imaging, University of Alberta, 2A2.41 Walter C Mackenzie Health Sciences Centre, Edmonton, Alberta T6G 2B7, Canada
Full list of author information is available at the end of the article

Abstract

Purpose: To evaluate the diagnostic accuracy of SPECT/CT arthrography in patients with suspected aseptic prosthesis loosening following hip and knee arthroplasty.

Methods: A retrospective review of 63 SPECT/CT arthrogram studies (36 knees and 27 hips) between February 1, 2013, and July 1, 2018, was conducted. All patients underwent clinical and radiologic evaluation as part of their assessment for persistent pain following hip and knee arthroplasty. The detection of tracer activity along the bone-prosthetic interface on SPECT/CT suggests aseptic loosening. Operative assessment as well as clinical/radiologic follow-up at a minimum of 1 year was used as the reference standard.

Results: The sensitivity and specificity of SPECT/CT for detection of aseptic loosening was 6/7 (86%) and 55/56 (98%), respectively. This gives a positive predictive value (PPV) of 6/7 (86%), a negative predictive value (NPV) of 55/56 (98%), and a diagnostic accuracy of 61/63 (97%).

Conclusion: SPECT/CT arthrography has a high diagnostic accuracy (97%) in the evaluation of loosening of both hip and knee arthroplasties in patients with persistent post-procedural pain.

Keywords: Total knee arthroplasty, Total hip arthroplasty, SPECT/CT, Loosening

2021
THA/TKA

SPECT-CT steigert
Sensitivität
Spezifität
Accuracy

Optimale Tracerlokalisation
Bsp. Pfanne THA

<u>Prinzip</u>:
Markiertes Kolloid intraartikulär
Tracer im Prothesenknocheninterface = Lockerung

Arthro SPECT-CT

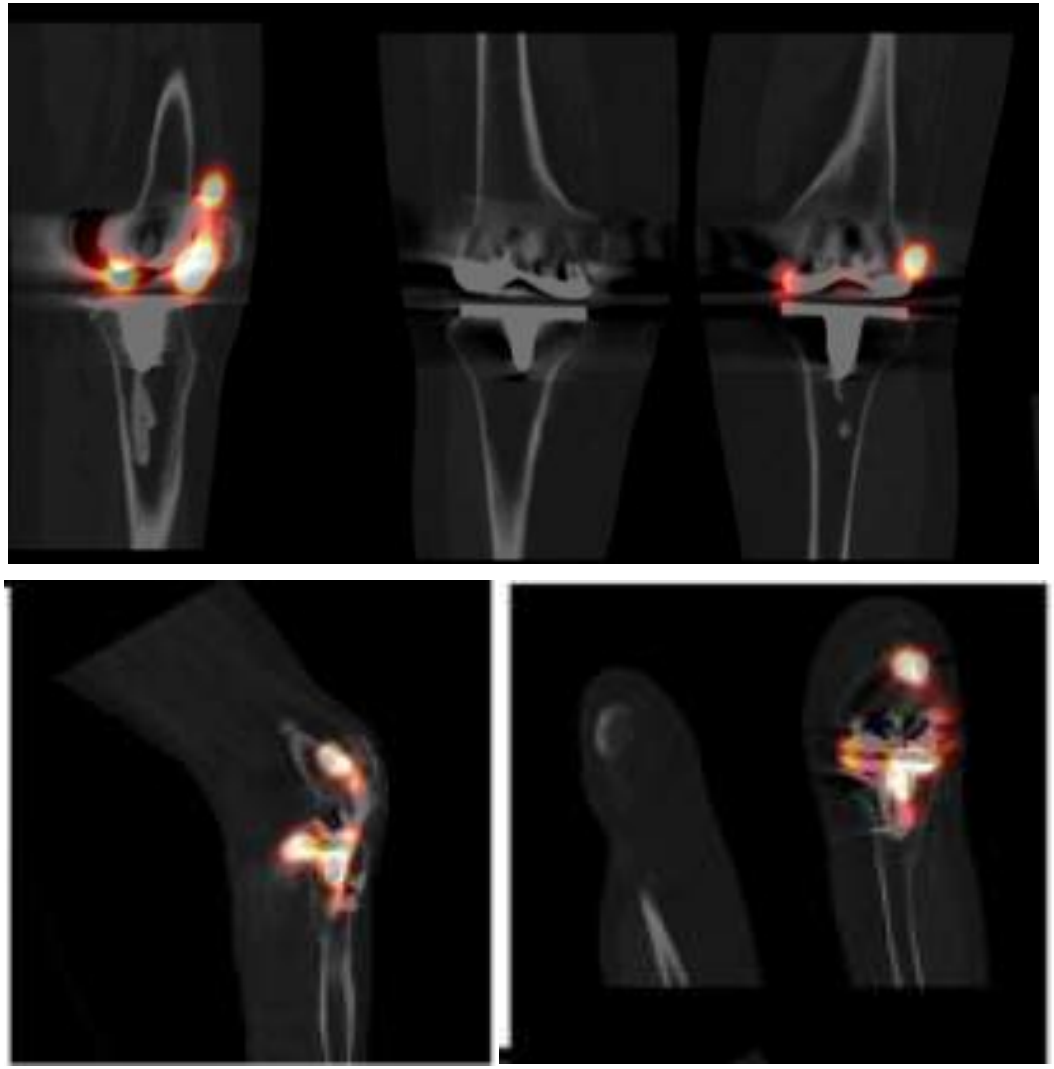

Nachteil:

Punktion erforderlich

- Duchleuchtung?
- Invasiv

Protheseninfektionen

VORTEIL SPECT CT

	Sens.	Spec.	PPV	NPV
planar	66	60	40	81
SPECT	89	45	40	91
SPECT-CT	89	73	57	94

Graute V, Feist M, Lehner S, Haug A, Müller PE, Bartenstein P, Hacker M. Detection of low-grade prosthetic joint infections using 99mtc-antigranulocyte SPECT/CT: Initial clinical results.
Eur J Nucl Med Mol Imaging 2010, Aug;37(9):1751-9.cds

Übereinstimmende Ergebnisse:

Schillaci O, Danieli R, Manni C, Simonetti G. SPECT/CT with a hybrid camera useful to improve scintigraphic imaging interpreta- tion? Nucl Med Commun 2004;25:705–10. doi:00006231- 200407000-00012 [pii].

Townsend DW, Cherry SR. Combining anatomy and function: the path to true image fusion. Eur Radiol 2001;11:1968–74. doi:10.1007/s003300101007.

Horger M, Eschmann SM, Pfannenberg C, Storek D, Dammann F, Vonthein R, et al. The value of SPET/CT in chronic osteomyelitis. Eur J Nucl Med Mol Imaging 2003;30:1665–73.

FDG – PET bei orthopädischen Infekten

LITERATURDATEN HETEROGEN

Autor	Pathologie	Sens. / Spez. /Acc
Manthey 2014	Protheseninfekt	82% / 87%
Familiari 2011	Diabetischer Fuss	43% / 67% / 54%
Kagna 2012	Diabetischer Fuss	100% / 93% / 96%
Chen 2010	THA	100% / 50 - 87%
Schiesser 2003	Implantatinfekt (Trauma)	100% / 93%
Chako 2002	THA	91,7% / 96,6%
Stumpe 2000	Knocheninfekt	100% / 83% / 99%

Sensitivität exzellent
Problem Spezifität !

Haben wir den optimalen Tracer?
Ga68 -FAPI - Einzelne Publikationen

Knieprothese Infekt

Schmerzhafte Knieprothese – Benefit genaue Lokalisation

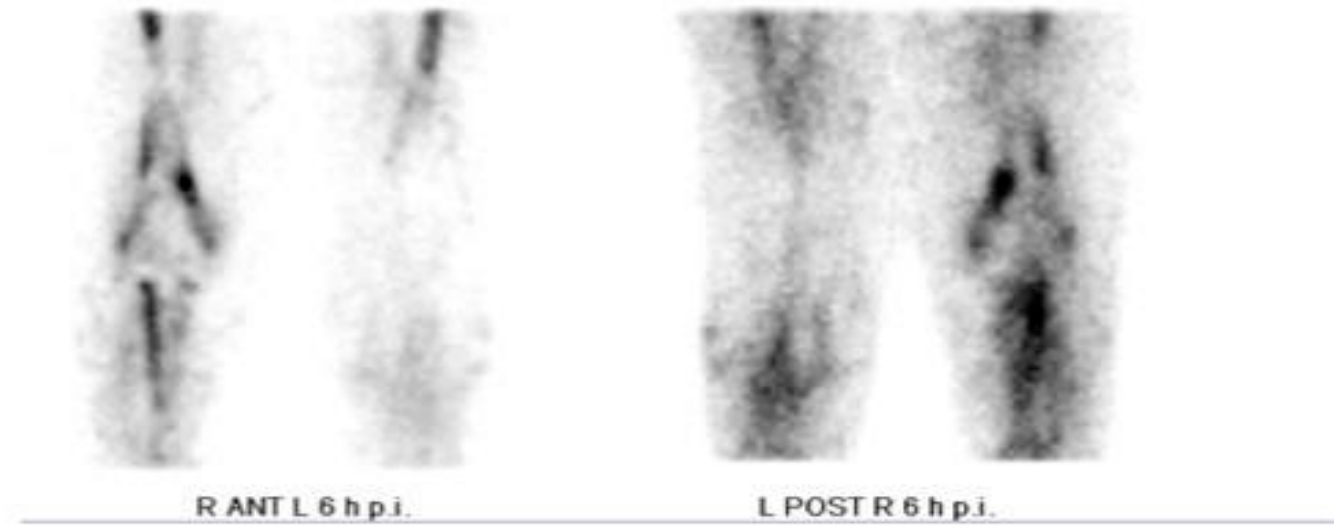



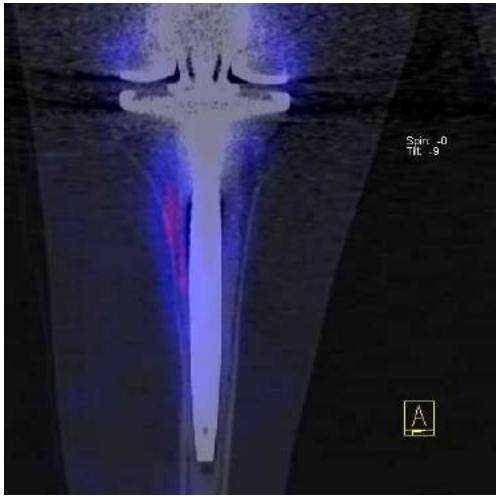

Protheseninfekte

Unabhängig vom Tracer gilt:

- Tracer Verteilung
- SPECT-CT :Genaue Lokalisation nur im Prothesenknochen-/Zementinterface

- Future: Quantifizierung?

Original article

Nuclear Medicine Communications

^{99m}Tc-HMPAO-WBC SPECT/CT versus ^{18}F-FDG-WBC PET/CT in chronic prosthetic joint infection: a pilot study

Johan Teiler[a,b], Marcus Ahl[c,d], Börje Åkerlund[c,d], Harald Brismar[e,f], Maria Holstensson[g,h], Stefan Gabrielson[a,i], Håkan Hedlund[e,j] and Rimma Axelsson[a,g]

Purpose The aim of this study was to compare ^{99m}Tc-HMPAO-WBC-SPECT/CT combined with ^{99m}Tc-nanocollloid SPECT/CT and ^{18}F-FDG-WBC-PET/CT combined with ^{99m}Tc-Nanocollloid SPECT/CT for the diagnosis and treatment evaluation of chronic prosthetic joint infection (PJI).

Methods Patients with suspected chronic PJI were examined with ^{99m}Tc-HMPAO-WBC SPECT/CT, ^{18}F-FDG-WBC PET/CT, and ^{99m}Tc-nanocolloid SPECT/CT (to visualize bone marrow). The location and patterns of uptake were noted and compared between the two leukocyte examinations. Both leukocyte examinations were evaluated visually for infection. The PET examinations were also evaluated semiquantitatively. Chronic PJI was verified clinically by microbial culture and successfully treated PJI was confirmed by 12 months symptom-free follow-up after cessation of antibiotics.

Results Nineteen patients were included with 10 hip prostheses and nine knee prostheses. Fourteen were diagnosed with chronic PJI and five with successfully treated PJI. The sensitivity of visual evaluation of ^{99m}Tc-WBC-HMPAO SPECT/CT for all joints was 0.31 and for ^{18}F-FDG-WBC PET/CT 0.38. The specificity was 0.80 and 0.83, respectively. All patients with a true-positive SPECT examination had a false-negative PET examination and vice versa. Semiquantitative evaluation of the hips gave an area under the curve of 0.905 using the iliac crest as the background. Semiquantitative evaluation of the knees did not produce significant results.

Conclusion This pilot study showed no difference in the sensitivity or specificity of ^{99m}Tc-HMPAO-WBC SPECT/CT and ^{18}F-FDG-WBC PET/CT when combined with ^{99m}Tc-nanocollloid SPECT/CT in the diagnosis or treatment evaluation of suspected late chronic PJI. *Nucl Med Commun* 43: 193–200 Copyright © 2021 Wolters Kluwer Health, Inc. All rights reserved.

Nuclear Medicine Communications 2022, 43:193–200

Keywords: biofilm, chronic infection, ^{18}F-FDG-WBC-PET/CT, nuclear medicine, PET, prosthetic joint infection, SPECT, ^{99m}Tc-HMPAO-WBC

[a]Division of Radiology, Department of Clinical Science, Intervention and Technology (CLINTEC), Karolinska Institutet, Stockholm, [b]Department of Radiology, Karolinska University Hospital, Huddinge, [c]Department of Medicine Huddinge, Karolinska Institutet, Stockholm, [d]Unit of Infectious Diseases, Karolinska University Hospital, Huddinge, [e]Division of Orthopaedics and Biotechnology, Department of Clinical Science, Intervention and Technology (CLINTEC), Karolinska Institutet, Stockholm, [f]Department of Orthopaedic Surgery, Karolinska University Hospital, Huddinge, [g] Functional Imaging and Technology, Department of Clinical Science, Intervention and Technology (CLINTEC), Karolinska Institutet, Stockholm, [h]Function Medical Radiation Physics and Nuclear Medicine, Karolinska University Hospital, Huddinge, Sweden, [i]Radiology Service, Christchurch Hospital, Christchurch, New Zealand and [j]Department of Orthopaedic Surgery, Visby Hospital, Visby, Sweden

Correspondence to Johan Teiler, MD, Karolinska Institutet, Stockholm, 14152, Sweden Tel: +46858584699; e-mail: johan.teiler@ki.se

Received 12 July 2021 **Accepted** 5 October 2021

-Cut off für aseptisch /septische Lockerung
- auch in mehreren FDG PET Studien

Kantonsspital Baselland

OSG PROTHETIK

OSG Prothetik Case 1

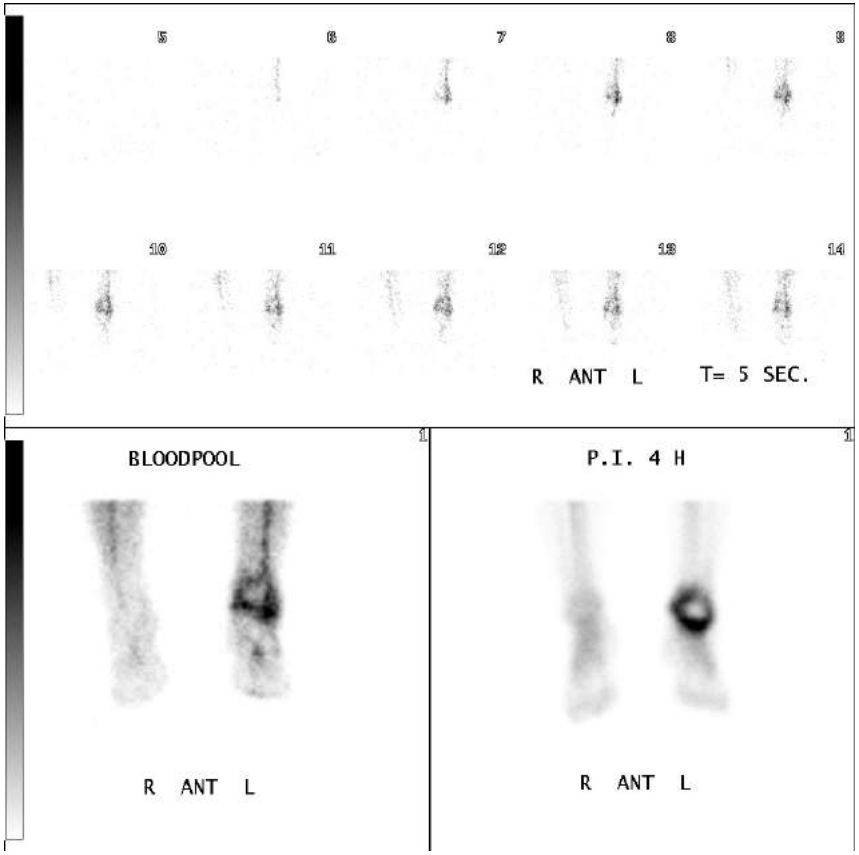

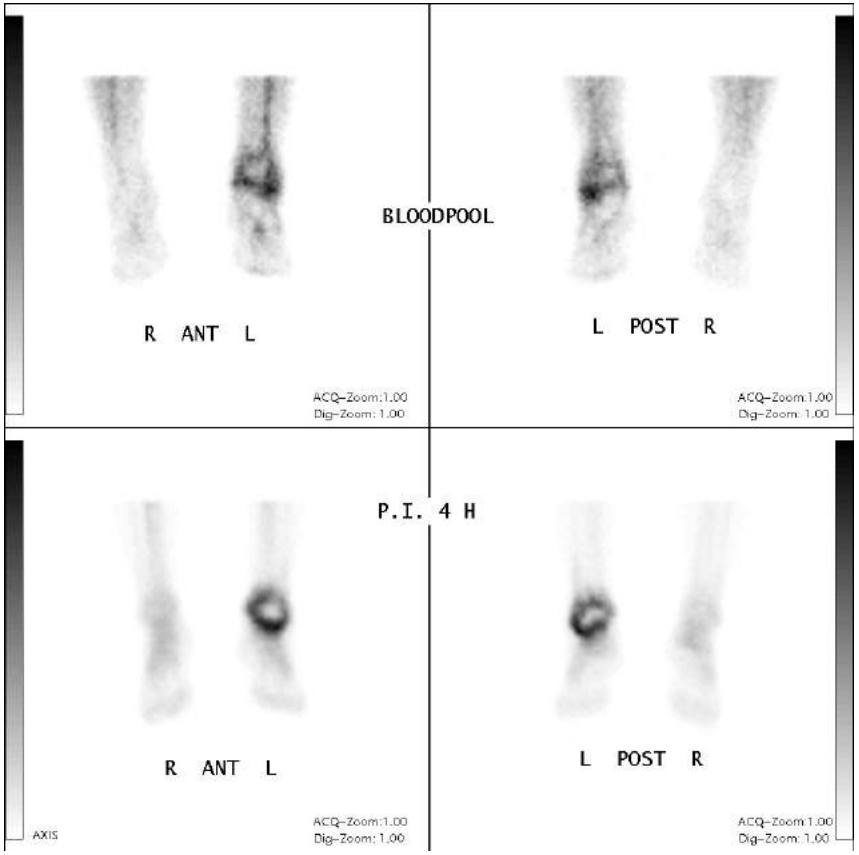

OSG Prothetik Case 1

Lockerung - Granulome

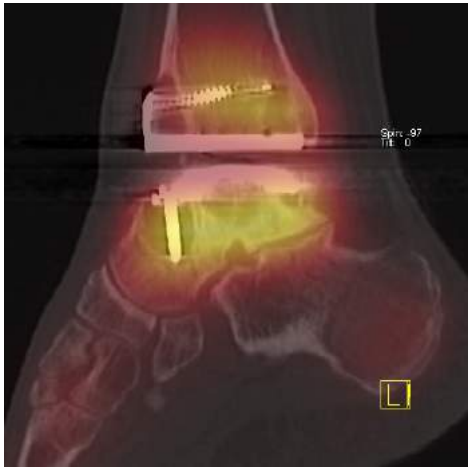

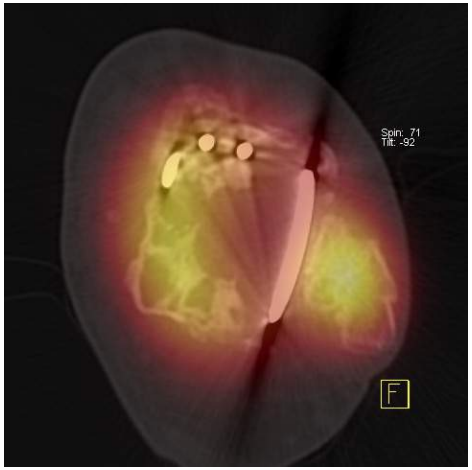

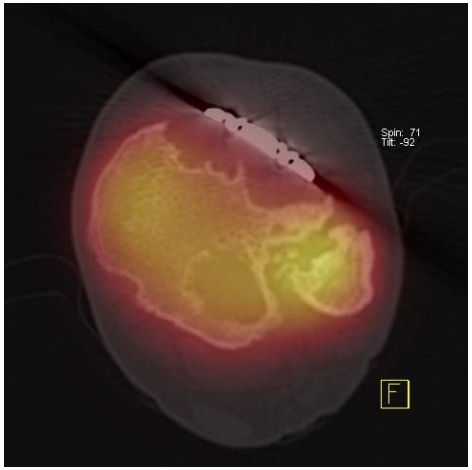

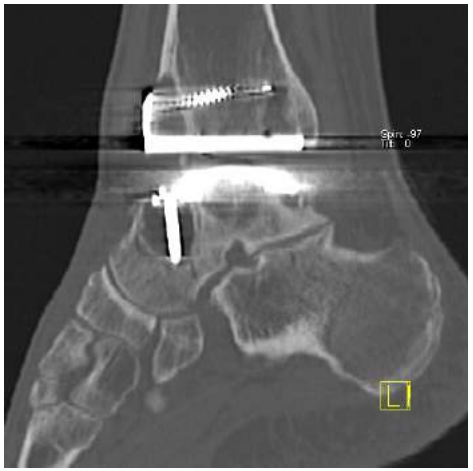

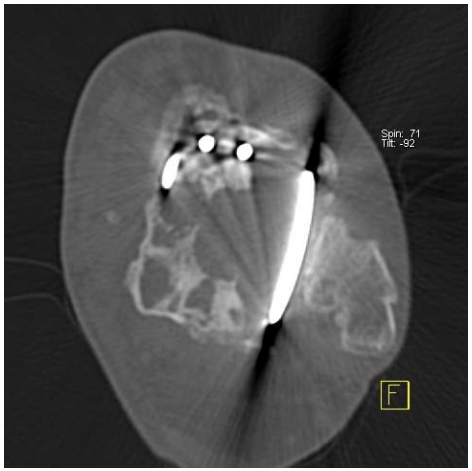

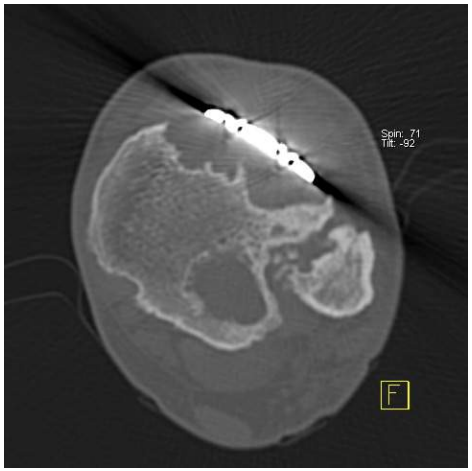

Kantonsspital Baselland

OSG Prothetik Case 1

Lockerung - Granulome. - ektope Ossifikationen

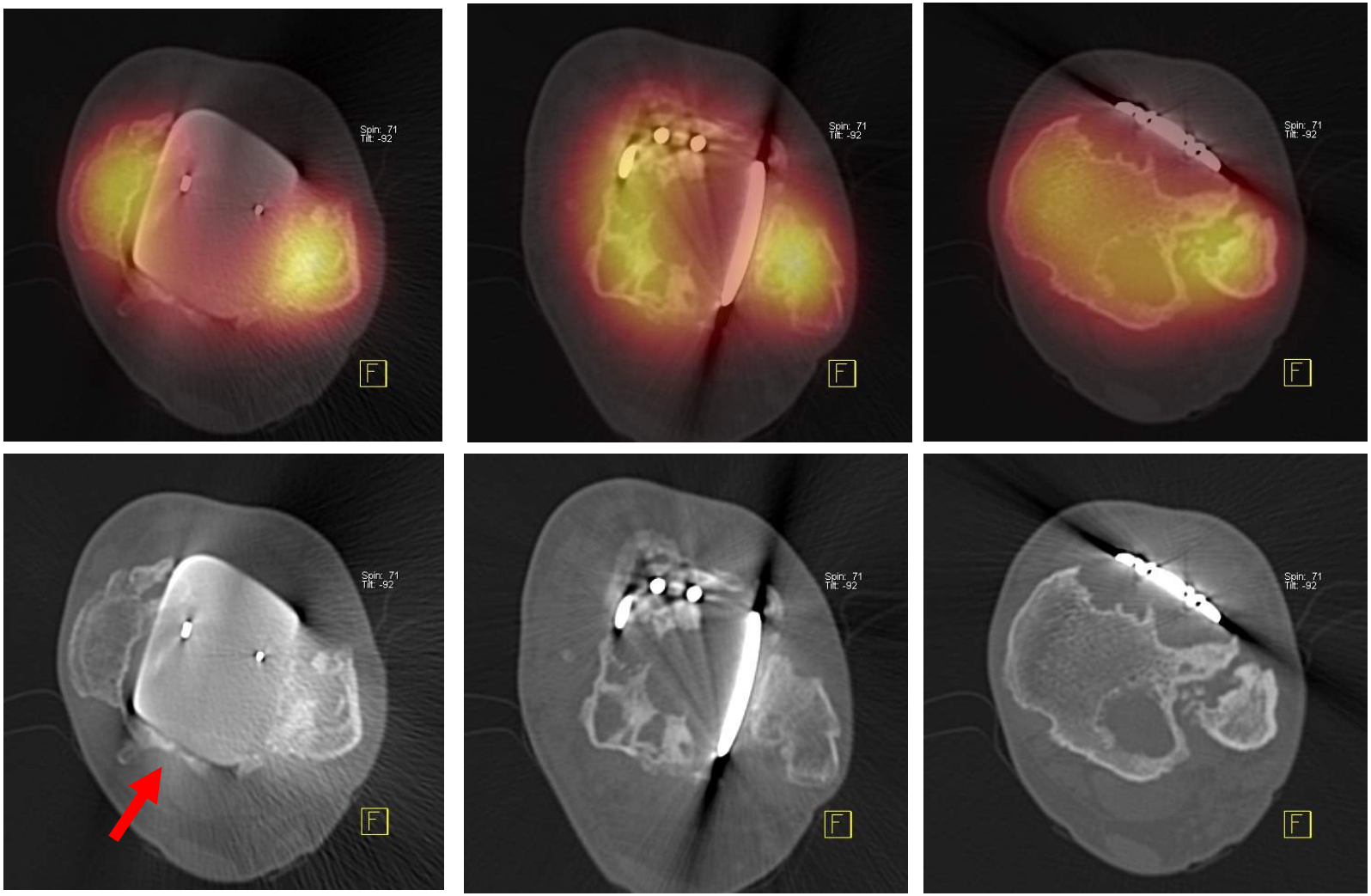

Kantonsspital Baselland

OSG Case 2

Osteomyelitis ? Wo ist der Infekt?

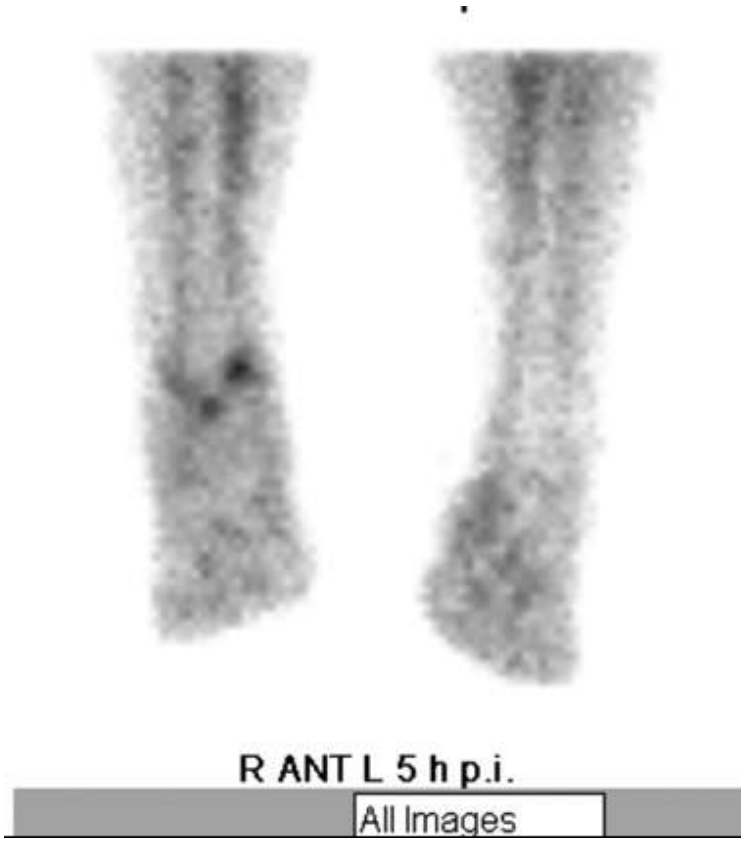

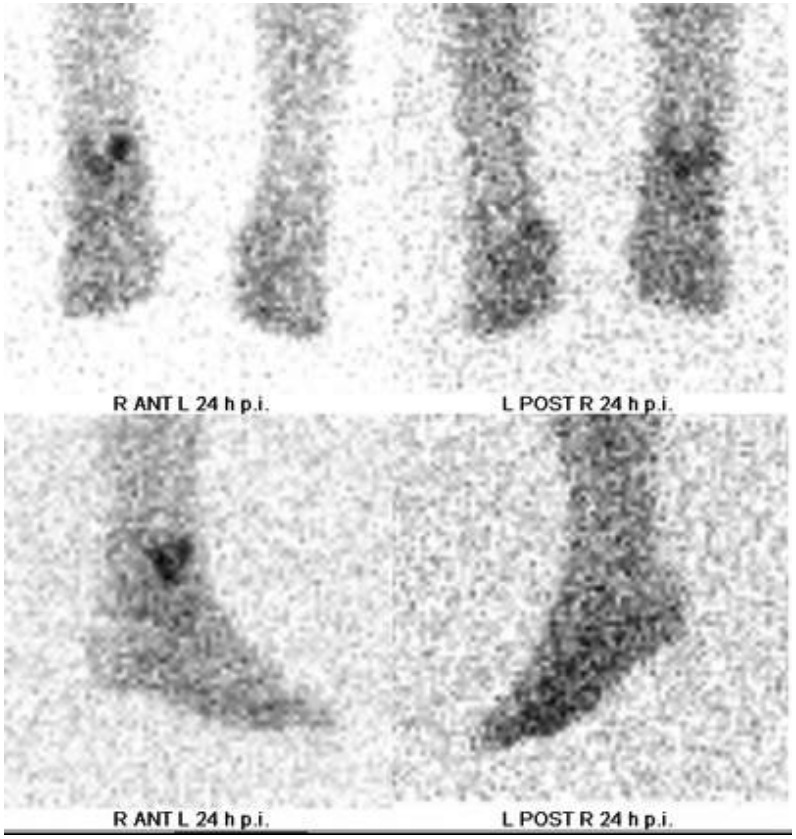

OSG Case 2

Osteomyelitis ? Wo ist der Infekt?

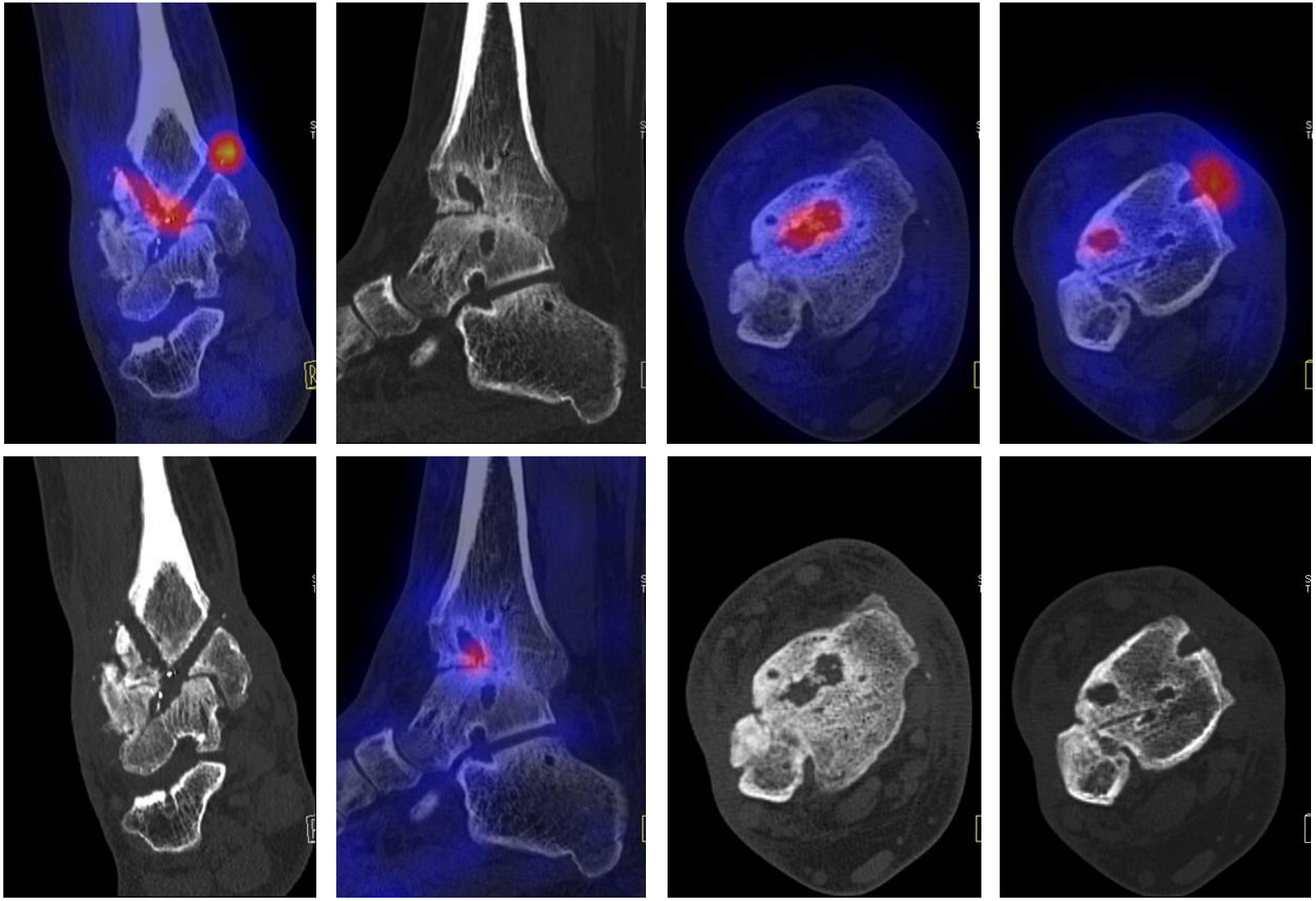

Diagnose – ein Puzzle

Multifaktorielle Problematik
Revision muss ALLE Ursachen berücksichtigen

SPECT	CT	
Biologie	Anatomie	
Knochenumbau	Knochenqualität	
Infekt	Genaue Lokalisation BTU	
Remodelling	Biomechanische Daten	
Belastungszonen Nachbargelenke!		

Zusammenfassung

SPECT CT ideales Ortho Tool (One Stop Shop):

- Kombination Metabolismus und Anatomie = Erhöhung der Spezifität
- Visualisierung der Knochenbiologie
- Metallartefakte beherrschbar – MRT?
- Überlegen Darstellung des kortikalen Knochens im Vgl. MRT
- derzeit beste Methode zur Prothesenbeurteilung
- Biomechanik aus 3-D Messungen möglich (Software)

SPECT-CT - Benefit oder „Nice“ to have?

BENEFIT

TAKE HOME MESSAGES

See the whole Picture

- Nutzung aller Informationen
  - Klinik
  - Prothesentyp? - Wo erwarte ich Uptake ? Wo soll es nicht „leuchten“?
  - Röntgen
  - CT
  - MRT

- Biomechanik berücksichtigen

- Klare Kommunikation (orthopädische Sprache)
  - Befundbeschreibung (Bsp. Grünzonen)

- Bilddokumentation standardisieren (Farbskala, Skalierung)

.....und zu Guter Letzt

Interdisziplinarität ein Muss

Prof. Dr. MT Hirschmann

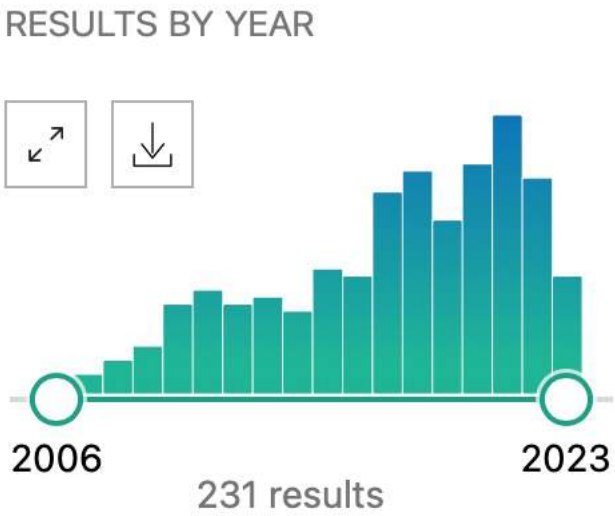






Vielen Dank für die Aufmerksamkeit
Fragen?